



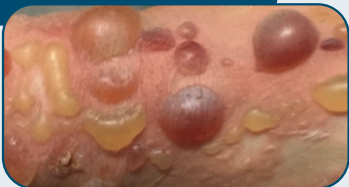**Bullous pemphigoid**

**What:** Itchy wheal like rash, followed by fluid filled blisters, with redness

**Why:** Autoimmune, medications for cancer, DPP4 inhibitors

**Treatment:** Steroid creams, steroid tablets, omalizumab injection, dapsone, doxycycline

**Outcome:** Good, dyspigmentation



**Remember**



- Bathe regularly
- Use mild soap or cleanser
- Consume food rich in antioxidants like citrus fruits

- Apply sunscreen even indoors
- Stay hydrated
- Moisturise thrice a day

**Medication and their side effects**

Medicine	Use	Skin changes
Statins	Reducing cholesterol	Dryness
Diuretics	Reducing blood pressure	Blistering / photosensitivity
ACEi	Reducing blood pressure	Itching
CCB	Reducing blood pressure	Gumenlargement /photosensitivity
Beta Blockers	Arrythmia, hypertension	Psoriasis
Sulfonyl urea	Diabetes	Pemphigus



**SIG**

Geriatric Dermatology  
(IADVL Academy)

For the use of a Registered Medical Practitioner or a Hospital or a Laboratory only.  
GGI-CO-A2-DMB-300008533-300008533-PE-121-481.

Brought to you by **Dr.Reddy's**



**SIG**  
**Geriatric Dermatology**  
(IADVL Academy)





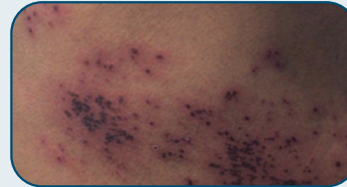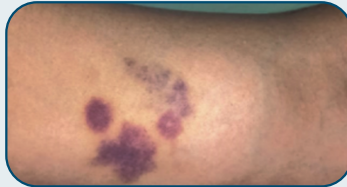
## Patient Information Material

Keeping skin Gold, even when Old



### Senile Purpura

**What:** Bruises seen on the back of hands, elbows  
**Why:** Skin becomes thin and fragile with age, sun damage, and medication  
**Treatment:** Sunscreen  
**Outcome:** Good, resolves in time

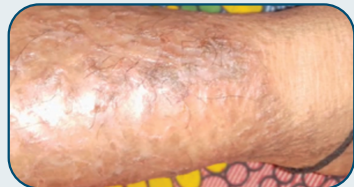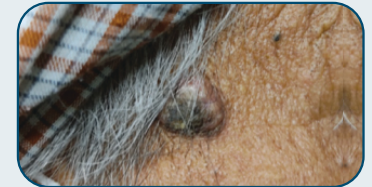


### Herpes Zoster

**What:** Painful, grouped blisters often usually on one side of body  
**Why:** Reactivation of dormant chicken pox virus  
**Treatment:** Antiviral medication, pain killers, antibiotic cream  
**Outcome:** Resolves, residual burning

### Basal cell carcinoma

**What:** Slow growing pearly / nodule that may ulcerate and bleed  
**Why:** Sun damage, immune suppression  
**Treatment:** Surgical removal  
**Outcome:** Good, if detected and removed early



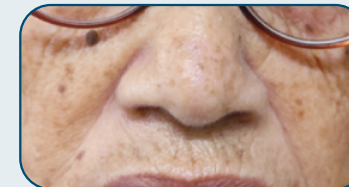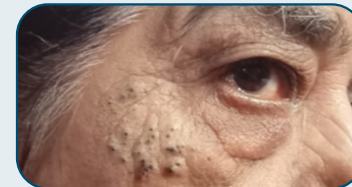### Asteatotic Eczema

**What:** Dry, itchy, flaky, crazy pavement skin  
**Why:** Low humidity, excessive bathing, detergents, medications  
**Treatment:** Moisturizers, short term steroid cream  
**Outcome:** Good, but likely to recur



### Photo-ageing

**What:** Sallow skin with black comedones, deep wrinkles  
**Why:** Chronic UV light exposure, air pollutants, smoking  
**Treatment:** Sunscreen, antioxidants  
**Outcome:** Prevention is better



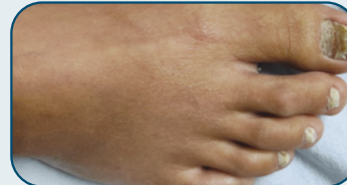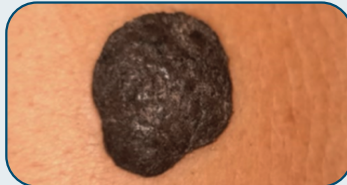### Actinic keratosis

**What:** Scaly yellowish spot on sun damaged skin  
**Why:** Photo ageing, sunburn, defective immunity  
**Treatment:** Cryotherapy, curettage, excision.  
**Outcome:** Small risk for skin cancer



### Seborrheic Keratosis

**What:** Brown warty lesions or spots, usually on face  
**Cause:** Minor trauma  
**Why:** Solar damage, medications  
**Treatment:** Shaving, cryotherapy, burning  
**Outcome:** Good, it is not cancer



### Onychomycosis

**What:** Streaky white plaques appear on nail, with subungual debris  
**Why:** Fungal infection  
**Treatment:** Antifungal tablets, nail lacquer, keeping nails dry  
**Outcome:** Good, requires time



### Wrinkles

**What:** Lines and furrows with loose skin  
**Why:** Skin becomes lax, irregularly thick and inelastic. Loss of fat  
**Treatment:** Botulinum toxin injection, fillers, cosmetic surgery  
**Outcome:** Good, resolves in time

