



IADVL

IADVL SIG DERMATOPATHOLOGY, Annual Newsletter (1st issue)

Issue: December, 2020



Dr Gopinathan Nair Nandakumar
Co-ordinator SIG Dermatopathology



Dr Chirag Desai
Convenor SIG Dermatopathology



Dr Neetu Bhari
Coordinator, Newsletter



Dr Vishal Gupta
Coordinator, Newsletter

Members

Dr. IS Reddy

Dr. Vishal Gupta

Dr. Rita V. Vora

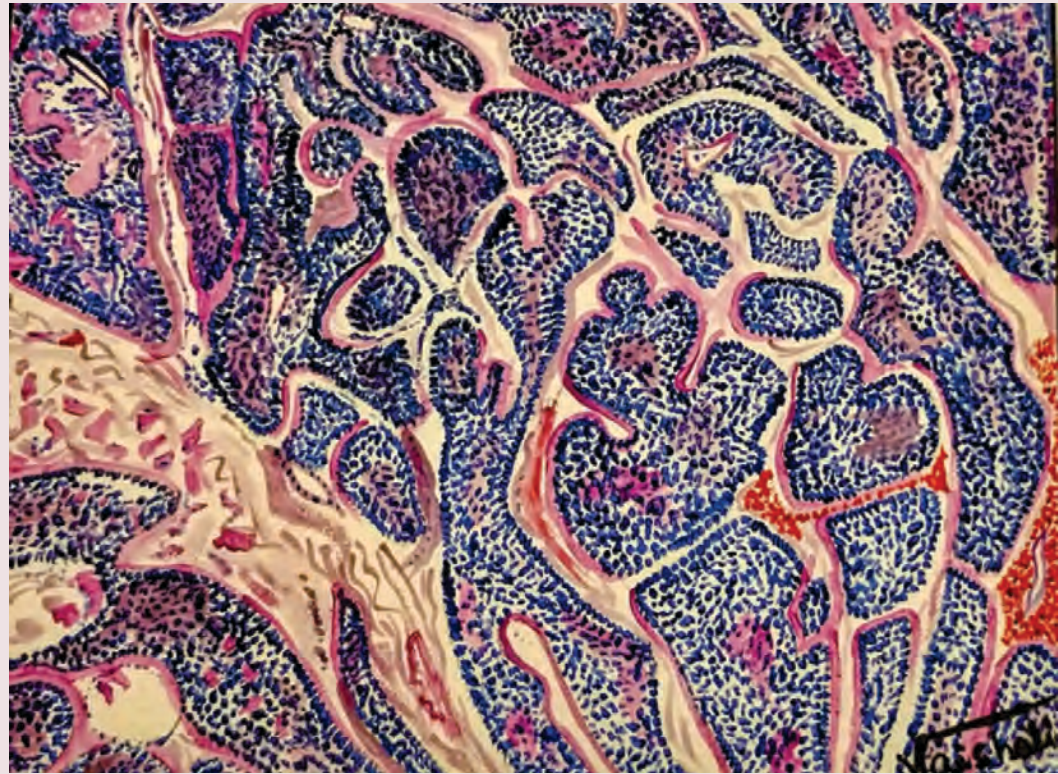
Dr. Geeti Khullar

Dr. Balkrishna Nikam

Dr. M Ramam

Dr. Sujay Khandpur

Dr. Neetu Bhari



Contents

1. Welcome note by editorial team.....	2
2. Case report: Ulcerated papules on the face: The beacon to an underlying duodenal adenocarcinoma...3	3
3. Art work.....	6
4. A talk with Dr. Uday Khopkar.....	7
5. Crossword.....	10
6. Quiz 1.....	11
7. Short-term dermatopathology training opportunities overseas.....	13
8. Epidermis made easy!!.....	16
9. Poem: Lichen planus- a better half !?.....	18
10. Mnemonics in Dermatopathology.....	19
11. Quiz 2.....	21
12. Poem: An eye underneath.....	29
13. Tips for obtaining optimal skin biopsy specimens in inflammatory dermatoses.....	30
14. Summary of a published article: Cutaneous protothecosis in an immunocompetent host.....	32
15. Review article: Deep learning in dermatopathology: Present scenario and future.....	35
16. "Dermatopathology" in "La La land".....	40
17. Answers to crossword, quiz 1 and quiz 2.....	41,42

Welcome Note

Dear All,

While the world is giving a tough fight to COVID 19 pandemic and we all have been transferred from a real world to virtual world of teleconsultations, webinars and online learning platforms. Even the socializing is now done virtually by means of various online applications. While we are coping with the 'new normal' , we have more time at hand and this is the time to learn, un-learn and re-learn many concepts. We, the team of SIG Dermatopathology proudly bring forth this newsletter fully loaded with interesting cases, puzzles, interview with a renowned Indian Dermatologist and Dermatopathologist, write-up on training opportunities in dermatopathology in India and abroad and many more interesting articles. We hope that all of you enjoy reading this newsletter and it plays a part in inspiring the young minds and enrich further the seasoned ones. Happy reading!

Editorial Team

Case Report

Ulcerated papules on the face: The beacon to an underlying duodenal adenocarcinoma



Dr. Utkrist Lahoria

(3rd year MD Student Dermatology, AIIMS Jodhpur)

Others Contributors and affiliations:

1. **Dr. Saurabh Singh** (Associate professor, Dermatology, AIIMS Jodhpur)
2. **Dr. Ranjana Beniwal** (SR Dermatology, AIIMS Jodhpur)
3. **Dr. Meenakshi Rao** (Associate professor, Pathology, AIIMS Jodhpur)

A 60-year-old man, under evaluation for abdominal pain, was referred to dermatology outpatient for asymptomatic lesions over face since 10 days. Clinical examination showed three erythematous, slightly violaceous lesions - two papules ranging in size from 0.2 to 0.5 cm over left temple and one papule of size 1×0.8 cm in the right nasolabial fold near ala (Fig 1a,b). All papules had central ulceration, and the nasolabial fold papule additionally showed haemorrhagic crusting. On palpation, they were firm in consistency and non-tender. Skin biopsy was obtained from the right cheek and left temple papules. Colonoscopy and upper gastro-intestinal tract endoscopy up to duodenum (D1 and D2) was normal. CT abdomen showed heterogeneous duodenal wall irregularity in D3/D4 with predominant extramural component extending into adjacent mesentery with vascular involvement, lymphadenopathy and focal lesions in liver, spleen and left adrenal gland. The punch biopsy showed an invasive tumour in the dermis composed of irregular glands lined by moderately

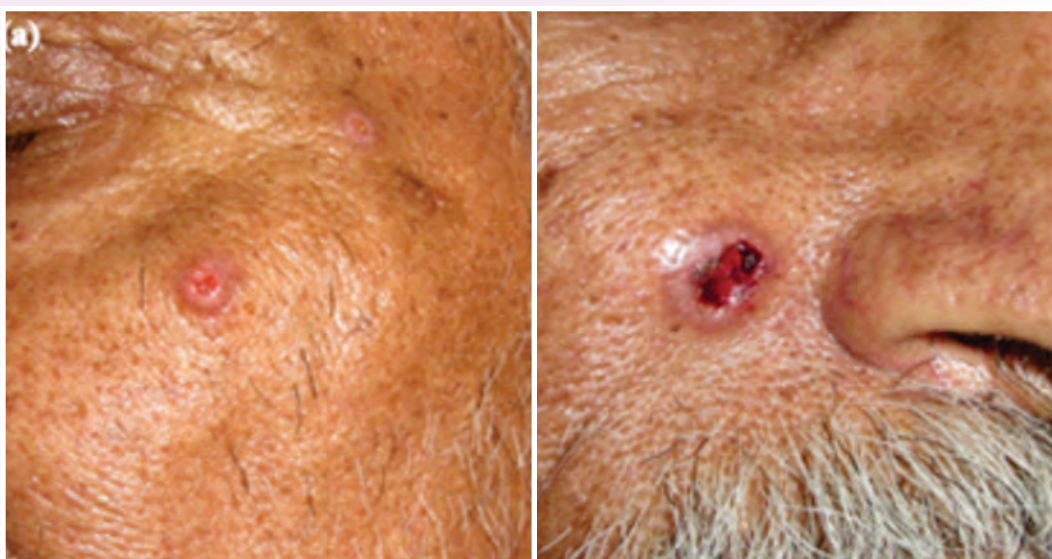


Fig 1 Erythematous to slightly violaceous ulcerated papules over the face.

pleomorphic cells exhibiting stratification. Mitoses were noted. Intraluminal neutrophilic exudate and focal intraluminal mucin was also noted. The tumour was resulting in ulceration of overlying epidermis (Figure 2 a,b). On immunohistochemistry, glandular cells showed strong positivity for CK7 and was negative for CK20, CDX2 and p63 (Figure 2c,d). The histological features were suggestive of metastatic deposits and primary carcinoma was confirmed to be moderately differentiated adenocarcinoma of duodenum on enteroscopic biopsy.

Cutaneous metastases represent 2% of all skin tumours and occur as forerunner of internal malignancy in around 1% of all carcinomas. They are usually multiple, metachronous and present with varied clinical morphology.¹ Cutaneous metastases

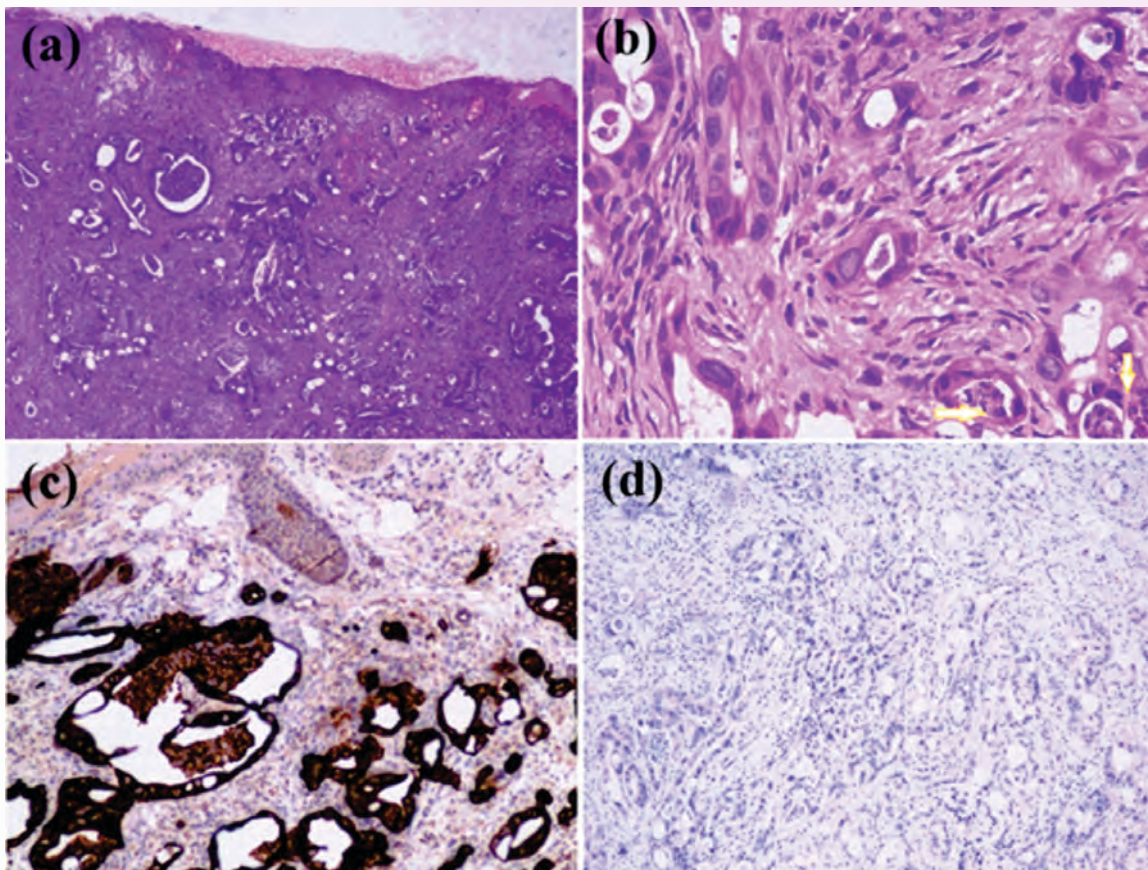


Fig 2 Histopathologic findings. (a) Collection of irregular and variably sized glandular structures in the dermis, with focal ulceration of the overlying epidermis (Haematoxylin and eosin, original magnification x 4). (b) Glands lined by markedly pleomorphic and bizarre cells with moderate cytoplasm, a few with intraluminal mucin and neutrophilic exudates. (Haematoxylin and eosin, original magnification x 40). (c) Tumourous glands showing diffuse CK7 positivity (Original magnification x 10). (d) Metastatic deposits showing negative staining for CK20 (Original magnification x 10).

from gastrointestinal tumours most frequently occur in vicinity of the primary tumour, like abdomen, perineum and favour sites of previous incision.² Metastasis to scalp, face and neck is rare.^{3,4}

Metastases from intestinal adenocarcinoma usually resemble the primary tumour and lack cutaneous adnexal differentiation. Though presence of 'dirty' necrosis i.e neutrophils and degenerate cells in the lumen of the glands is a pointer to the colorectal origin of the metastases, it was seen in this case of metastatic deposits from duodenal adenocarcinoma. However, CK20 negativity along with diffuse and strong positivity for CK7 supported the duodenal origin. As far as ascertained, facial cutaneous metastases from the small intestine have not been reported.^{1,3}

Cutaneous metastases may resemble many cutaneous adnexal tumours. Histopathologically, location of tumour in deep dermis or subcutaneous tissue, multifocality and presence of lymphovascular invasion suggest metastases. Features such as connection with the epidermis or growth within skin adnexa (in situ component) or the presence of a benign counterpart component (eg. melanocyte) within lesion support primary cutaneous origin. Immunohistochemistry panels comprising p63, podoplanin (D2-40), CK5/6 and calretinin have also shown high sensitivity and specificity in the distinction, with primary skin tumors showing positive expression.⁵

Cutaneous metastases may signal to a clinically silent visceral tumour or give clue to tumour recurrence or other distant site metastases. They require a high index of suspicion as well as close histological evaluation to reach a diagnosis as they portend poor prognosis.

References

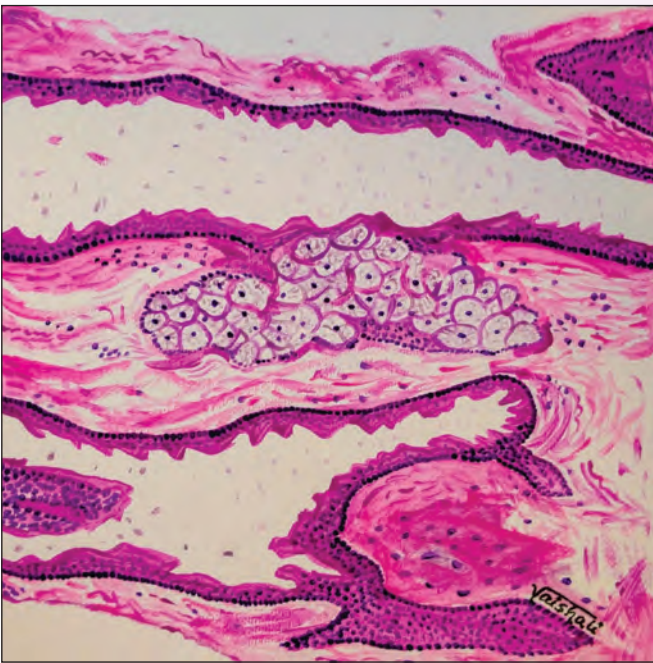
1. Guanziroli E, Coggi A, Venegoni L, *et al.* Cutaneous metastases of internal malignancies: an experience from a single institution. *Eur J Dermatol.* 2017; 27: 609-14.
2. Lookingbill DP, Spangler N, Helm KF. Cutaneous metastases in patients with metastatic carcinoma: a retrospective study of 4020 patients. *J Am Acad Dermatol.* 1993; 29: 228-36.
3. Stavrianos SD, McLean NR, Kelly CG, *et al.* Cutaneous metastasis to the head and neck from colonic carcinoma. *Eur J Surg Oncol.* 2000; 26: 518-9.
4. Lifshitz OH, Berlin JM, Taylor JS, *et al.* Metastatic gastric adenocarcinoma presenting as an enlarging plaque on the scalp. *Cutis.* 2005; 76: 194-6.
5. Danialan R, Mutyambizi K, Aung PA, *et al.* Challenges in the diagnosis of cutaneous adnexal tumours. *J Clin Pathol.* 2015; 68: 992-1002.

Art Work

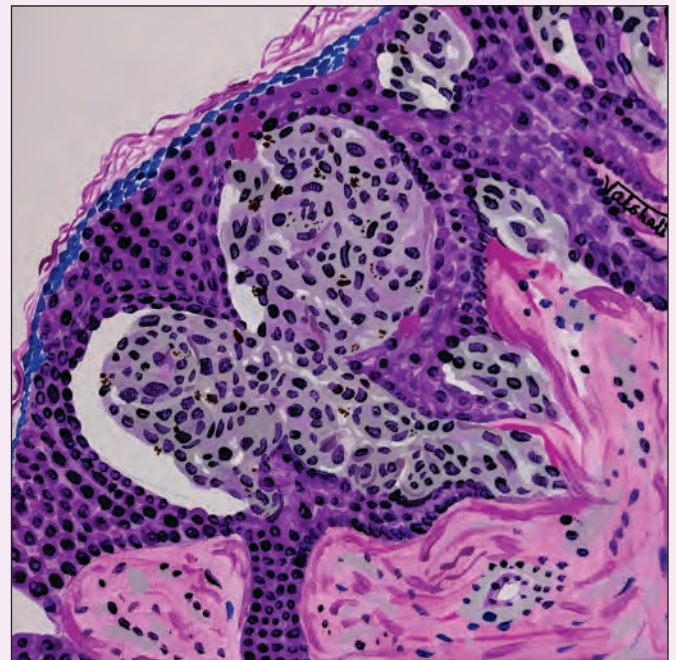


Dr. Vaishali Masatkar

*Dermatopathology fellow and Research Scholar
Wake Forest University school of Medicine,
Winston Salem, NC (USA)*

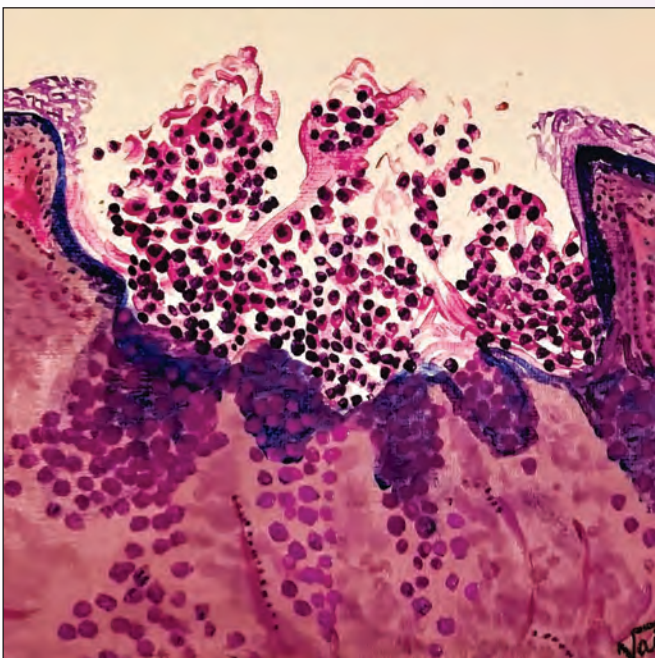


A cyst lined with a thin squamous epithelium with eosinophilic cuticles and associated with sebaceous glands. This art is representative of **Steatocystoma**



Molluscum contagiosum with a crater filled with eosinophilic to basophilic viral inclusions with extrusions of molluscum bodies.

Histopathologic representation of **Spitz nevus** with spindled and epithelioid melanocytes in hanging banana/raining down appearance with overlying artifactual clefting and eosinophilic kamino bodies



A Talk with Dr. Uday Khopkar

Good morning Sir,

A very warm welcome to the talk for the very first edition of the annual newsletter of SIG Dermatopathology. It is my pleasure to share this space with you sir, and I hope through this many young dermatologists get some bits of huge wisdom from you.

Thank you, Indu.

Dr. Indu: I have always wondered and still do: Who should be called a dermatopathologist?

Dr. Uday Khopkar: Any dermatologist or pathologist who has enough training or fellowship in dermatopathology can be called a dermatopathologist. For a dermatologist, it is important to have a formal pathology training, and same for a pathologist to have a clinical rotation in dermatology.

Dr. Indu: is there a particular time duration for the same?

Dr. Uday Khopkar: Umm, see it is difficult to exactly tell the duration or say the number of slides to point out like that. I cannot say that you must have seen 10,000 slides or something like that. It is difficult to define a time frame for adequate training.



Dr.Khopkar with his past fellows/students of dermatopathology

Dr. Indu: what do you think is the space dermatopathology has in dermatology pertaining to present situation? And do you think that a resident must have enough knowledge of it during residency?

Dr. Uday Khopkar: Dermatopathology is no doubt a very important aspect because it not only helps in diagnosis but also guides us in treatment. But now, the situation is different, we have dermatopathologists who can help in reading the slide which means you can escape having a thorough knowledge on this subject. So, even if you don't read your own slide, you can get it read by a dermatopathologist. Earlier, it was important as there were not many dermatopathologists, and therefore dermatologists used to see and read their slides. I believe every college should have a dermatopathologist.

Dr. Indu: what inspired you to learn Dermatopathology? Was it interest driven or learning generated more interest and curiosity to you?

Dr. Uday Khopkar: In our times, dermatologists used to read their own slides. Now there is advantage of get reporting from colleagues trained in dermatopathology.

I was very blessed to have my mentors and guides who used to see their own slides and that brought interest to me. Then, I got fellowship in NYU in Dermatopathology where I met Dr. Bernie Ackerman. This was for a short duration, but I got immense encouragement and support from my seniors. After completing the brief period, I went again for a year.

Dr. Indu: please share some memorable experiences about your fellowship?

Dr. Uday Khopkar: Yes, It was a great experience with lots of fond memories. I was involved in few researches under Dr. Bernie. That time we didn't have the luxury of internet and used to do our research in libraries. I cannot forget those times and got to learn a lot. I did a research on Artifacts in histopathology with Dr. Bernie because we don't have such a great processing facility in India. Though the work didn't get published but it taught me a lot. My next project with Dr. Bernie was on 'silhouette of section' and Dr Bernie was very interested in studying the stratum corneum patterns of the section. Dr. Ackerman was very kind to put my name in his book for our work. Generally, every student used to have one project, but I had two. These were very fond memories working with him.

Also to mention, we used to wake up at 5 am and rush otherwise you wouldn't get a seat. And we used to see thousands of slides daily. So, it was great fun.

Dr. Indu: one thing or learning that stayed with you and you would like to pass on?

Dr. Uday Khopkar: Yes, it is very important to be true with your findings. I wanted to teach and pass the knowledge to my students who could then teach other interested students in other medical colleges.

Dr. Indu: after coming to India, how did you start your journey here and from where the idea of fellowship arose and why it was called diagnostic dermatology?

Dr. Uday Khopkar: (Laughs) It was a little difficult in those days. We used to have monocular microscopes, so you can imagine. But as I mentioned, there was always huge support and help from everybody I worked with. Gradually I started fellowship under MUHS (Maharashtra University of Health Sciences) and am very happy to see my students learning Dermatopathology.....

When I started the fellowship course, it was more clinically oriented and meant for dermatologists. So, it was more of diagnostic dermatology. Over the time, I received requests for including pathology students. During last several years, many pathology residents were posted with me and they have shown exceptional interest and commitment to attending my dermatopathology sessions.

Dr. Indu: what are your expectations from your fellows?

Dr. Uday Khopkar: I would like if they join some medical college, continue to teach and see the slides. Even if you are in private practice, you can continue to see the slides.

Dr. Indu: what are the valid tips and suggestions you would like to give to a beginner who is just starting to report slides.

Dr. Uday Khopkar: Yes, if you are reporting you should make sure that you are true to your findings. Send the reports at time and don't delay much.

Dr. Indu: what to do when there are clinical differentials and histopathological differentials are also almost the same? Shall we just write the findings or chose one diagnosis.

Dr. Uday Khopkar: In that case, you should try to get some clinical details and simplify, or give your best diagnosis with the scope for clinicopathological correlation by the referring dermatologist.

Dr. Indu: sometimes we get pictures and details by our colleagues and tend to see them before seeing the slide and get biased.

Dr. Uday Khopkar: (Laughs) Whatsapp asks you, I guess, before you download the image. See it after you have seen the slide.

Dr. Indu: do you think one gets stereotyped as dermatopathologist if they are reporting the slides, even if they deal with all other aspects of clinical dermatology as well.

Dr. Uday Khopkar: Umm, dermatopathology is a very integral part of dermatology. I don't think so. I consider myself more as a clinician.

Dr. Indu: can a person do everything, I mean like dermatopathology and aesthetics and dermatosurgery.

Dr. Uday Khopkar: (Laughs) It is difficult for a person, but if someone is capable enough to manage, may be. But dermatopathology is something which needs at least a year of training and needs practice. But yes, if you have a private practice, you have to think of revenue as well and you can't stop doing procedures.

Dr. Indu: lastly what do you think is the position of dermatopathology in India and scope of teledermatopathology?

Dr. Uday Khopkar: Dermatopathology in India is growing, and must continue to grow with teaching and training more and more residents. I wish to have a dermatopathologist in each college, so there is no problem for interested residents to learn. Teledermatopathology is a bit difficult, but we have advancing technology. I hope we find it out very soon. Actually, Digiscan is very costly and impractical to be there with all, but we have alternative advancements also coming up.

Dr. Indu: one book on dermatology if you have to name.

Dr. Uday Khopkar: Andrews'

Dr. Indu: one book on dermatopathology if you have to name.

Dr. Uday Khopkar: Weedon's

Dr. Indu: you are a great teacher and a clinician. What do you think you enjoy the most?

Dr. Uday Khopkar: (Laughs) I think it is connected. You learn more from your patients, and then you teach. Both are very important.



Interview by

Dr Indu Kumari

Consultant Dermatologist,

All India Skin and Hair hospital, Delhi

Dermatopathology Crossword

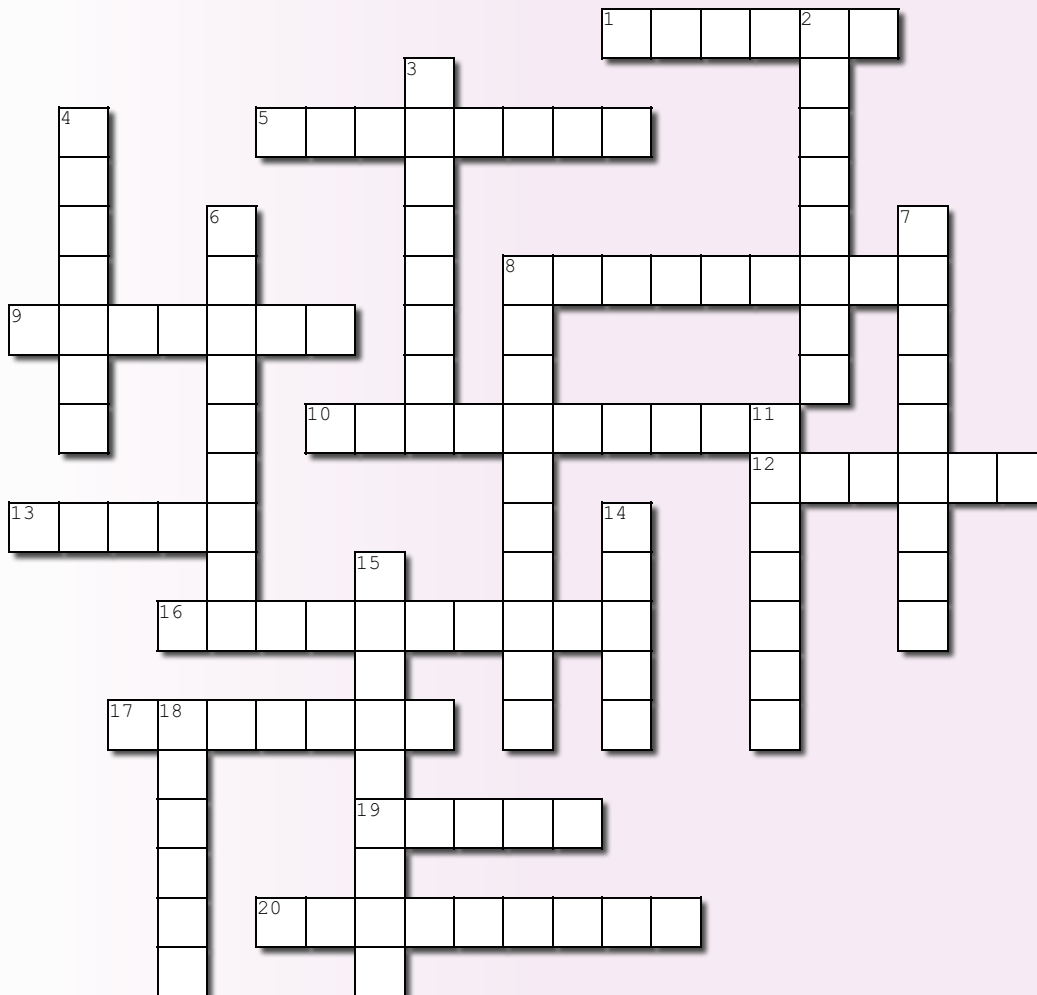
Complete the crossword puzzle below, based on signs, appearances, eponyms in dermatopathology



Dr. Anuradha Priyadarshini

Assistant Professor, Dept of Dermatology

SriRamachandra Institute of Higher Education and Research (SRIHER) Porur, Chennai



Created using the Crossword Maker on TheTeachersCorner.net

Across

1. pieces of the puzzle on the turban snuggle
5. fence around the collection of life and death
8. Reminiscent of graveyards, in a grave bullous disease
9. behold ye diamonds in a red 'glance'
10. pretty french 'round bodies' amidst the dirty warty ones
12. garland of flowers you find in this fatty giant
13. pus adorns psora's horn
16. atypical cells between the bundles, 'one at a time'(5,4)
17. like bulbs around a mirror, the bodies appear
19. burning bright in wells figures are swell
20. strawmats and whorls in tumour benign

Down

2. celestial bodies, link naked collections to rose thorns
3. radiating around emptiness within the nodules subcutaneous
4. stacked like yellow grains on their cob
6. its flying away in complete disarray
7. tilted tier in horny layer, thus the collarette appear
8. army of odd blue ones, summoned to base(3,7)
11. trilayered inside the porcelain-white dells
14. tumours of dermis zoned clear of epidermis
15. clubbed like the hoofs of desert's brute (5,4)
18. sign so 'dear' when lacy pigmentation in flexures appear

Quiz 1

(Single best response type)



Dr Anju George C

*Post graduate resident,
Department of Dermatology, AIIMS Raipur*

- Pendulous melanocytes are typical feature of
 - Melanoma
 - Melasma
 - Congenital melanocytic naevus
 - Blue nevi
- Acantholytic dyskeratosis is seen in all except
 - Dariers disease
 - Grovers disease
 - Hailey hailey disease
 - Pemphigus
- Factor XIIIa is an immunoperoxidase antigen for
 - Dermatofibroma
 - Rhabdomyosarcoma
 - Leiomyoma
 - Angiosarcoma
- Reticulin fibres can be better stained with
 - Silver stain
 - Sudan red
 - PAS
 - Verhoeff van gieson
- Which of the following is not a giant cell?
 - Starbust
 - Touton
 - Florette
 - Rosette
- Process of transepidermal elimination not seen in?
 - Pseudoxanthoma elasticum
 - Solar elastosis
 - Lichen nitidus
 - Molluscum contagiosum
- Ballooning degeneration is seen in all except
 - Herpes zoster
 - Erythema multiforme
 - PLEVA
 - Urticaria
- Which of the following is not a content of Michel's transport medium?
 - Potassium/sodium citrate buffer
 - Magnesium sulphate
 - Sigma
 - Ethanol
- Polarizing microscopy can be useful in all these except
 - Amyloidosis
 - Gout
 - Trichothiodystrophy
 - Hidradenoma
- Morula like appearance seen in
 - Coccidiomycosis
 - Rhinosporidiosis
 - Prothecosis
 - Chromoblastomycosis
- Ravelled wool appearance is seen in
 - Elastosis perforans serpiginosa
 - Pseudoxanthoma elasticum
 - Tendinous xanthoma
 - Granuloma annulare
- Windblown appearance in dermatopathology is seen in
 - Bowens disease
 - Actinic keratosis
 - Seborreic keratosis
 - Dariers disease
- Staghorn appearance is seen in all except
 - Habers syndrome
 - Galli galli disease
 - Dowling degos disease
 - Seborreic keratosis

14. All are physiological named bodies in dermatopathology except
- a. Glomus bodies
 - b. Lamellar bodies
 - c. Weibel palade bodies
 - d. Kamino bodies
15. Conchoidal bodies is another name of
- a. Schaumann bodies
 - b. Asteroid bodies
 - c. Lafora bodies
 - d. Verocay bodies
16. Lipschutz bodies is another name of
- a. Cowdry A bodies
 - b. Negri bodies
 - c. HP bodies
 - d. Guarnieri bodies
17. Totobodies seen in
- a. Hodgkins lymphoma
 - b. Epulis fissuratum
 - c. Sarcoidosis
 - d. Mucopolysaccharidosis
18. All of these are diagnostic histopathologic bodies in neoplasia except
- a. Russel bodies
 - b. Kamino bodies
 - c. Psammoma bodies
 - d. Rushton bodies
19. Palisaded appearance seen in all except
- a. Granuloma annulare
 - b. Necrobiosis lipoidica
 - c. Syphilis
 - d. SCC

Short-term Dermatopathology Training Opportunities Overseas



Dr. Sherina Laskar

MD, DNB, Msc

Locum Consultant in Dermatology, Basildon and Thurrock University Hospital, UK

People who make significant changes in their careers often have multiple reasons contributing to their decision and it was no different for me when I left my secure medical college job in Assam to move to the UK last year. There is a fantastic, much coveted, 2-year dermatopathology fellowship for dermatology or pathology trained doctors at St. John's Institute of Dermatology at Guy's and St Thomas' Hospitals in the UK that has rolled out scores of successful dermatopathologists over the years who now work across the globe. The fellowship does pay a salary which, while being adequate to sustain oneself with, may be a limitation for midcareer professionals, especially ones with families. To apply for the fellowship, one must be registered with the UK General Medical Council (GMC). This was my initial trigger for seeking to take the Professional and Linguistics Assessments Board (PLAB) test and eventually for moving to the UK.

There are at least a couple of other ways for an Indian dermatologist (or pathologist) to secure GMC registration. The Medical Training Initiative (MTI) scheme through which one gets sponsored for GMC registration without taking any exam is quite popular, but has its drawbacks and limitations. The other path for registration would be to take all three steps (part 1, 2 and PACES) of the Member of the Royal College of Physicians (MRCP) exam (or Royal College of Pathologists exam for pathologists), which might seem arduous, but would go a long way to get on the Specialist Register either through the Certificate of Specialist Registration (CESR) route or by getting on the UK training pathway.

This article is on short term observerships or fellowships in dermatopathology and I have been obviously guilty of meandering so far. For the dermpathology-naïve pathologist and (especially) dermatologist wishing to be thoroughly trained, I would advocate at least 1 year or ideally 2 years of training at any institute reporting at least 10,000 cases a year. Anything short of 12 months would best be regarded as short term training and can vary from a few days to a few months. The following would be the reasons for doctors to look for short term training:

1. To have a taster session to decide if one's heart lies in dermatopathology.
2. For a brush up of previously acquired skills that have gone rusty.
3. To learn more about specific areas of dermatopathology such as the pathology of alopecia, nail, soft tissue, vulval/penile diseases or skin cancer.
4. As a requirement for career advancement or professional development programs.

In another article that I have previously written for the Indian Journal of Dermatology, Venereology and Leprology (IJDL), I have written in detail about comprehensive dermatopathology training programs in India and abroad and also listed a few short-term training options. A few useful courses in the UK, EU and the US are listed below.

1. **The London Diagnostic Dermatopathology Course:** This is 5-day course is run chiefly by Dr Eduardo Calonje, who is one of the current editors of McKee's Pathology of Skin and Director of Dermatopathology at St John's Institute of Dermatology. He is globally hailed as a soft tissue expert. There are also other eminent faculty members teaching on this comprehensive course for beginners which has a rich collection of slides. Two scholarships are awarded each year to applicants from different countries to attend the course. Details are available on the dedicated website <https://londondiagnosticdermatopathology.com/programme/>
2. **ABCD course (London):** This is 'A Basic Course of Dermatopathology' run by Dr Catherine Stefanato and Dr Blanca Martin, both dermatopathology consultants at St John's Institute of Dermatology, London. The three-day course is perfect for beginners and attendees would be treated to Dr Stefanato's innovative teaching skills and benefit from her expertise in alopecia.
3. **Summer Academy of Dermatopathology (Graz, Austria):** This is an enriching 5-day intensive course led by the acclaimed lymphoma expert, Dr Lorenzo Cerroni along with other eminent speakers from the US, UK and other EU countries.
4. **Online course by Derspath Pro:** A vast selection of slides of varying levels of difficulty are accessible at affordable prices on 6, 12 and 24 month subscriptions on the Derspath Pro website. The contributors include eminent dermatopathologists such as Dr Uma Sundram (US), Prof Phillip McKee (US), Dr Richard Carr (UK) and Dr Arti Bakshi, a postgraduate from PGIMER, Chandigarh, who is now settled in Liverpool, UK. The website also has information on a soft tissue pathology course.
5. **Annual meetings of American Society of Dermatopathology (ASDP), International Society of Dermatopathology (ISDP), United States and Canadian Academy of Pathology (USCAP), Australasian Dermatopathology Society (ADS):** these are 3 to 5-day conferences that have excellent collection of slides and lecture sessions that are useful for updating one's knowledge and skills.

Most eminent dermatopathology consultants and practitioners usually accept international observers for 4 weeks or more when written to and also waive off fees. My IJDL article titled 'Training avenues in dermatopathology for an Indian dermatologist or pathologist' (DOI: 10.4103/ijdl.IJDL_546_17) has more details on popular dermatopathologists to train under. My friend, Dr Dinesh Pradhan, who is a dermatopathologist working in Aurora Diagnostics, Florida highly

recommends Dr Victor G. Prieto, Pedram Gerami, Associate Chair and Professor of Pathology at MD Anderson Cancer Center, Houston for detailed learning about melanocytic lesions, and Pediatrics at Pedram Gerami, of Northwestern University, Chicago for focused molecular dermatopathology and Dr Clay Cockerell of Cockerell Dermatopathology for a wealth of cases. Dr Pradhan also suggests names of other dermatopathologists of note who are great teachers such as Drs. Philip LeBoit and Boris Bastian at University of California San Francisco, Martin C. Mihm, Harvard Medical School, Dirk Elston, Medical University of South Carolina (elstond@musc.edu), Steven Billings, Cleveland Clinic, Ronald Rapini, University of Texas, Hafeez Diwan, Baylor College of Medicine and David Elder of the University of Pennsylvania.

One would need to decide on and factor in practical considerations such as travel and living expenses, leave from work, interruptions to private practice and support from family before deciding where and when to seek observerships. It is usually difficult to come across scholarships for short term training, but travel grants are awarded from time to time by international dermatology or dermatopathology societies to cover part of the costs.

To sum up, when one encounters a lull in one's career as a dermatologist or pathologist, a short term observership or course would be the right spark to get back in focus. I would welcome any queries regarding any aspect of this topic on my email address: sherina7@gmail.com.

Inputs from:

Dr Dinesh Pradhan, MD, DABP, FCAP, FASCP

Dermatopathologist and Medical Director

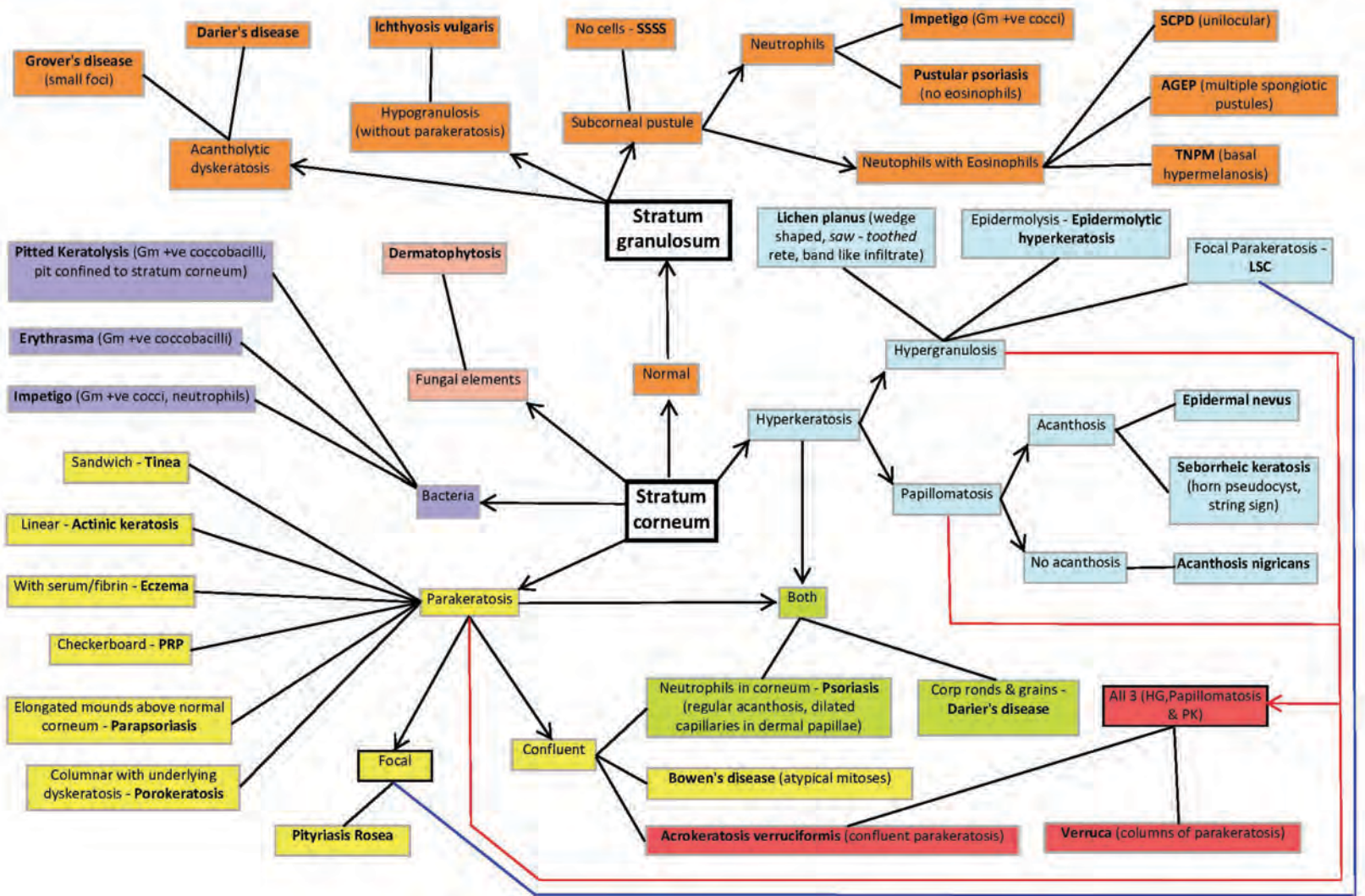
Aurora Diagnostics

Jacksonville, Florida, USA

Epidermis Made Easy



Dr. Saurabh Raut
Senior Resident, Department of Dermatology, AIIMS Raipur



Poem



Dr. Saurabh Singh

*Associate Professor of Dermatology,
AIIMS Jodhpur*

Lichen planus- a better half !?

Whether it is the actual hue,
or variants wider than the view.
You keep expanding the panorama,
still retaining your enigma.

I thought your love was superficial,
and your epidermal attack was ferocious.
But when you scratched papillary dermal,
the intent was even deeply malicious.

Searching for all your histopath qualities at once,
makes life truly and fairly unsatisfactory.
Colloid or granulosis or saw toothing an ounce,
making do with few as they come is savory.

Diagnosis is doubtful not so oft,
scopy or biopsy or clinical pointers so soft.
Yet pillar to post you made me run,
CPC and slotting into subtype seems fun.

You might rule any part of my body and soul,
The clinically itch-free life is my goal.
In between the peace and furore of the purple wife,
Your returning tendency says that your love for skin does thrive.

Mnemonics in Dermatopathology



Dr. Vijayasankar Palaniappan

Senior Resident

Department of Dermatology, Venereology and Leprosy
Sri Manakula Vinayagar Medical College and Hospital
Pondicherry

Other Contributors :

Dr. Karthikeyan Kaliaperumal

Professor & Head of the Department

Department of Dermatology, Venereology and Leprosy
Sri Manakula Vinayagar Medical College and Hospital
Pondicherry

1. Atrophic collagenosis (Decreased dermal thickness)

Learn	-	Linear atrophoderma of Moulin
About	-	Acrodermatitis chronic atrophicans
Reasons for	-	Restrictive dermopathy
Focal	-	Focal dermal hypoplasia
Atrophic	-	Aplasia cutis congenita
Collageneosis	-	Corticosteroid induced atrophy

2. Differentiating trichoepithelioma from BCC

Choosing	-	Clefts not present Trichoepithelioma over
Basal	-	Bcl-2 expression only by basal layer cells
Cell	-	CD34+ stromal cells around the island
Carcinoma	-	CD20+ Merkel cells present
Requires	-	Ruptured keratinous cysts
Proficiency	-	Papillary mesenchymal bodies

3. Parasitised macrophages

Dermatologist	-	Donovanosis
Resides in	-	Rhinoscleroma
HILL	-	Histoplasmosis, Lepromatous leprosy, Leishmaniasis
ToP	-	Toxoplasmosis, Penicilliosis

4. Primary scarring alopecia – Based on infiltrates

❖ Lymphocytic infiltrates

Lymphocytes	-	Lichen planopilaris
Are	-	Alopecia mucinosa
Killer	-	Keratosis Follicularis Spinulosa Decalvans
Cells with	-	Central centrifugal alopecia
Dense nucleus &	-	Discoid lupus erythematosus
Polyribosomes	-	Pseudopelade of Brocq

❖ **Neutrophilic infiltrates**

Neutrophils form

- First line - Folliculitis decalvans
- Defense against - Dissecting cellulitis of scalp
- Tissue damage - Tufted folliculitis

❖ **Both lymphocytic and neutrophilic infiltrates**

Both lymphocytes and neutrophils are

- Active - Acne keloidalis
- Against - Acne necrotica
- Extracellular pathogens - Erosive pustular dermatoses of scalp

5. Grenz zone

- Generally - Granuloma faciale
- Lazy - Lepromatous leprosy
- Louse - Leishmaniasis (Post Kala Azar Dermal)
- Likes to - Lymphocytoma cutis
- Live in - Leukemia cutis
- Dark - Dermatofibroma
- Environment - Erythema elevatum diutinum

6. Eosinophilic panniculitis

- The - Toxocariasis
- Dermatology - Drug reactions
- Is - Injection granuloma
- An - Arthropod bite
- Easily - Erythema nodosum / Eosinophilic cellulitis
- Volatile subject - Vasculitis

7. Angiofibromatous reaction pattern

- Angiofibromatous - Adenoma sebaceum
- Pattern is - Periungual and subungual fibromas
- A - Acquired acral fibrokeratoma
- Form of - Fibrous papule of the nose
- Minor reaction - Myxovascular fibromas (Familial)
- Pattern - Pearly penile papules

Quiz 2



Dr. Afroz Alam

2nd Year MD Student, Department of Dermatology, AIIMS Jodhpur

Other Contributors

Dr Saurabh Singh

Associate Professor

Department of Dermatology, AIIMS Jodhpur

IMAGE CONTRIBUTORS:

Dr. Saurabh Singh (Associate Professor, Department of Dermatology, AIIMS Jodhpur)

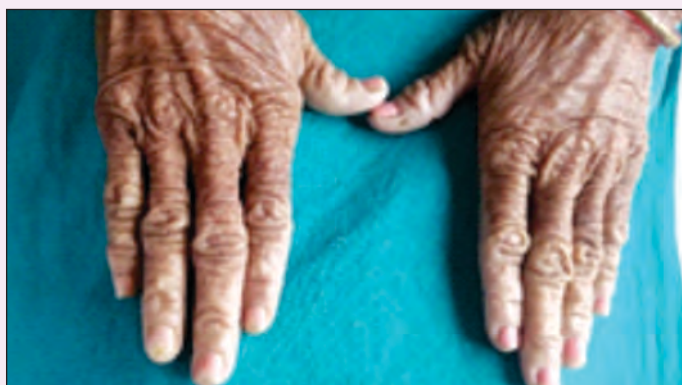Dr. Jyotsna Bharti (Associate Professor, Department of Pathology, AIIMS Jodhpur)

Dr. Ravi Mudugal (SR, Department of Dermatology, AIIMS Jodhpur)

Dr. Sahiba Rafi (2nd year MD student, Department of Dermatology, AIIMS Jodhpur)

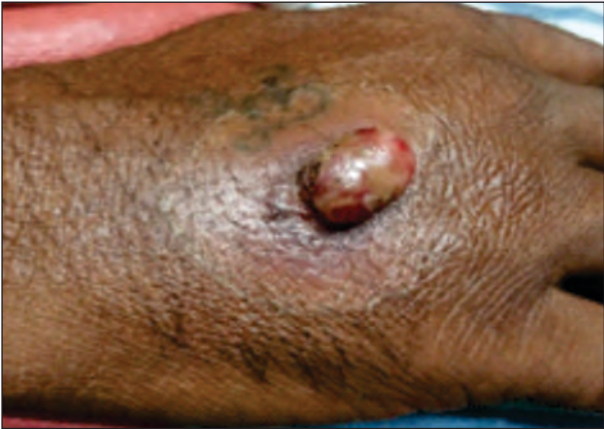Dr. Utkrist Lahoria (3rd year MD student, Department of Dermatology, AIIMS Jodhpur)

Q1. A 60-year-old Indian female farmer presented with multiple skin coloured to smooth waxy appearing papules over the dorsae of the hands, forearms, V-area of chest, neck and face over last 7 years which gradually increased in number and size. No systemic symptoms and blood investigations were significant. Histopathology showed large nodular eosinophilic deposits with clefts within the dermis along with special stains. A diagnosis of colloid milium was made. What stains and characteristics on immunohistochemistry may help differentiate Adult colloid milium from other close differentials?



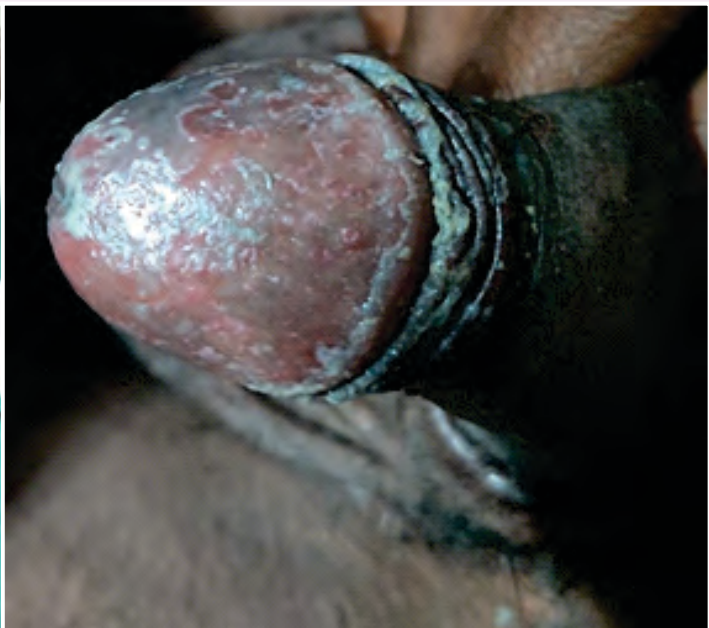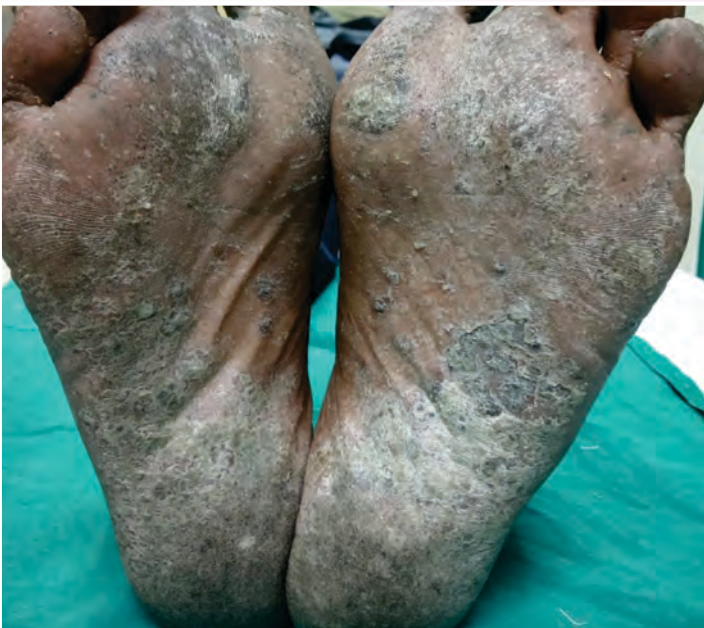1. Positive for Alcian blue, Amyloid and PAS with Positive cytokeratin
2. Positive for PAS with negative Alcian blue, amyloid and cytokeratin
3. Positive for PAS, cytokeratin and Negative for amyloid and Alcian blue
4. Positive for Amyloid and Alcian Blue and Negative for PAS and Cytokeratin

Q2. A 25 year old man presented with a nodule over the dorsum of right hand which achieved the size within 3 weeks and had history of occasional bleeding from the lesion. The lesion was excised and sent for biopsy . Which of the following statement regarding the diagnosis is false



1. HPE may show discrete masses or lobules composed of variably dilated network of blood capillaries
2. Epulis of Pregnancy is a related special sub group
3. HPE shows multiple granulomas with dilated capillary vessels and groups of vascular tufts
4. Common benign vascular tumour of mucous membrane and skin

Q.3 A 35 year old male truck driver by occupation presented to the OPD with 4 months of papulosquamous lesions over the body , palms and soles associated with diarrhoea and polyarthrititis with swelling of hands and feet. Few superficial ring shaped erosions over the glans were present. Which feature is not helpful in diagnosis ?



1. Psoriasis hyperplasia with thicker horny layer
2. Histopathological features resemble psoriasis
3. Spongiform Pustulation with exocytosis of neutrophils
4. Symmetric oligoarticular arthritis is a criteria to reach a diagnosis

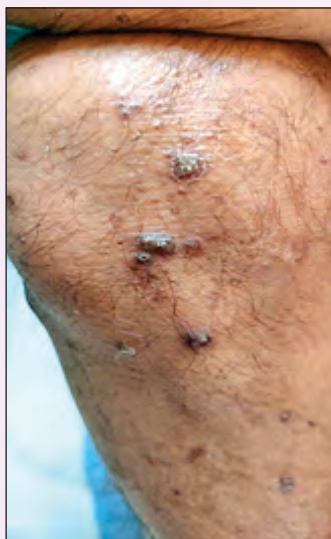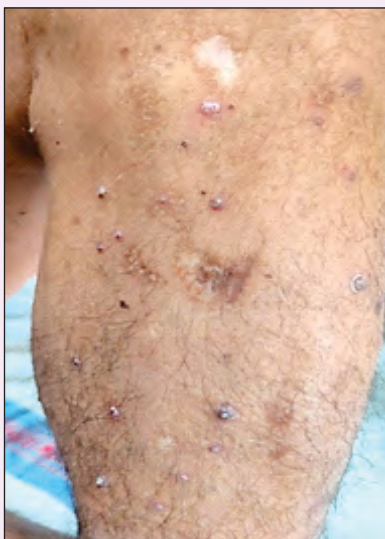Q4. A 35 year old male presented to the OPD with multiple fluid filled flaccid blisters over the body which ruptured within 3-4 days. Patient also complained of oral erosions which were painful in nature. Histopathology showed intraepidermal blister with acantholytic cells. DIF was positive. Which of the following statements is false regarding the diagnosis?

1. Positive anti Dsg 3 ELISA can be used as a predictor of relapse
2. Positive DIF can be used as a predictor of relapse
3. Sensitivity for Diagnosis of pemphigus : ELISA>IIF
4. Sensitivity for correlation with disease activity: IIF>ELISA

Q5. Subepidermal disorders are usually being diagnosed by using an analysis pattern called serration analysis. Find the odd one out regarding this analysis in the following options?

1. Bullous Pemphigoid
2. Mucous Membrane Pemphigoid
3. Bullous SLE
4. Anti p200 pemphigoid


Q6. A middle age male presented to the OPD with multiple round hyperpigmented papules with central keratotic plug over the extremities associated with pruritis. Patient is a known diabetic and had HBA1c of 12.5 %. Which of the following stains will not be helpful in reaching a diagnosis ?



1. Histologically characterized by transepidermal elimination of dermal material
2. Special stain Trichrome will be helpful in reaching a diagnosis
3. HPE may show crateriform epidermal invagination filled with necrotic material and inflammatory cells
4. Characterised by transepidermal elimination of elastin

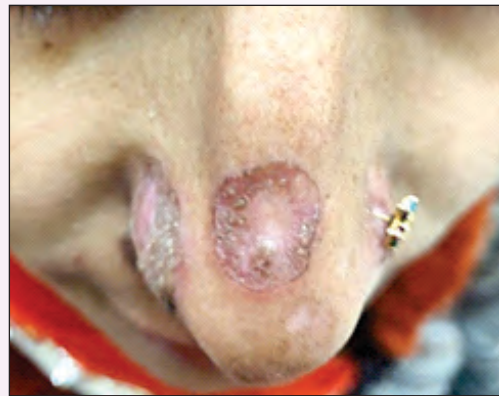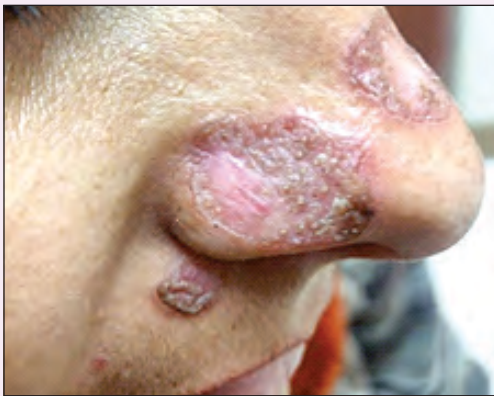Q7. Match the following with the corresponding signs seen in histopathology of fungal infections?

Image source- google



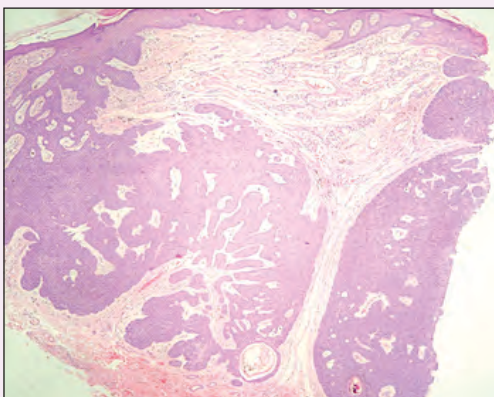
	A	B	C	D
1.	Sporotrichosis	Paracoccidioidomycosis	Blastomycosis	Chromoblastomycosis
2.	Sporotrichosis	Chromoblastomycosis	Paracoccidioidomycosis	Blastomycosis
3.	Blastomycosis	Chromoblastomycosis	Lobomycosis	Sporotrichosis
4.	Lobomycosis	Paracoccidioidomycosis	Chromoblastomycosis	Sporotrichosis

Q8. A middle aged female presented with erythematous lesions over the nose as seen in the figure. Which is the histological feature not correlating towards the clinical diagnosis ?



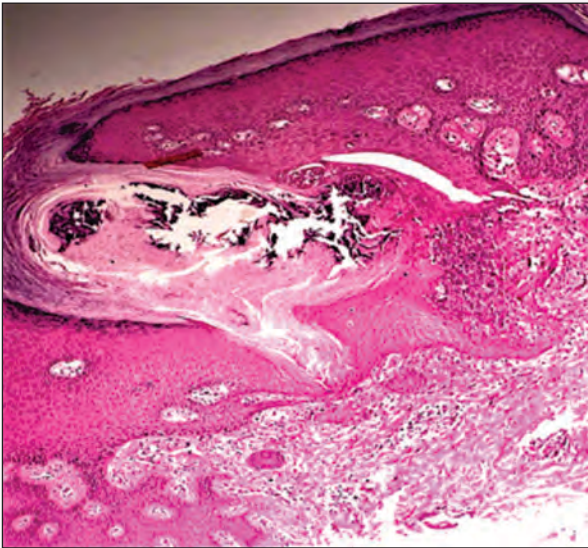
1. Hyperkeratotic stratum corneum with a thin column of parakeratotic cell
2. Cornoid lamellae is pathognomic of the disease
3. Granular layer below the cornoid lamellae is absent or markedly reduced
4. Cornoid Lamellae can be found in viral warts, nevoid hyperkeratosis, actinic keratosis

Q9. Which of the following is true regarding retraction spaces in histology of basal cell carcinoma?



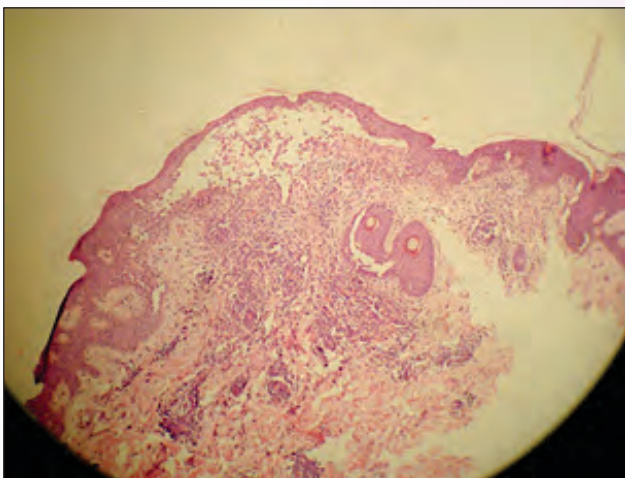
1. In certain instances can be related to mucinous deposits of hyaluronic acid and dermatan sulphate
2. This morphological feature can be used as a diagnostic clue
3. More commonly related to artefacts produced during fixation and dehydration of biopsy specimen
4. These lacunae are present at the centre of the epithelial nests

Q10. A 22 YR old male presented to the OPD with an annular plaque over the extremity with variably crusted erythematous papules at the periphery and central scarring. There is a history of penicillamine intake for treatment of WILSON disease. Histopathology is given in the below figure. Which of the following statement is false?



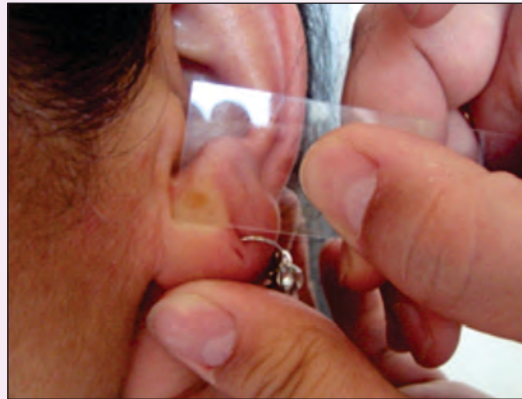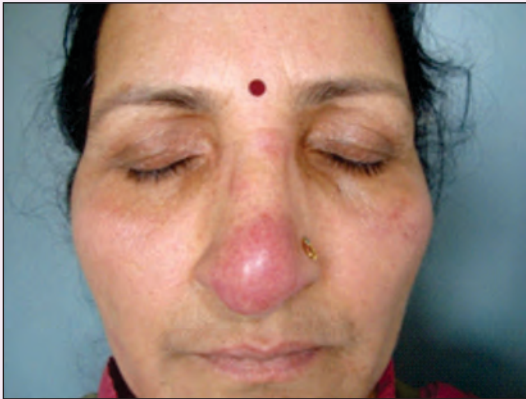1. The disorder suggests of a transepidermal elimination disorder
2. Special stain used is VerHoeff Van gieson stain
3. The disorder is most common in females and mostly has an Autosomal dominant inheritance
4. Histology shows elimination of Elastin

Q 11. A middle age male presented with oral erosions associated with flaccid blisters over the body with the following histology. Which of the following statement is wrong?



1. Hair follicle biopsy would also be helpful even if the patient has no scalp lesions
2. Early lesions of the disease may show eosinophilic spongiosis
3. Characteristic histological finding is subcorneal blister with acantholysis
4. Sensitivity of DIF is 90-100 percent

Q 12. Which of the following is correct about the disease in the images:-



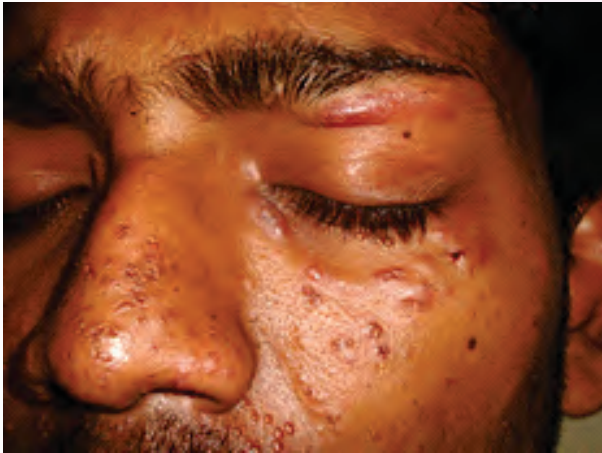1. Schaumann bodies in biopsies help rule out TB definitively
2. Elevated angiotensin converting enzyme is sensitive marker of sarcoidosis but lacks specificity
3. Polarizable foreign bodies, if found on microscopy, exclude the diagnosis
4. Knees should be examined for ruling out erythema nodosum associated sarcoidosis

Q 13. Regarding the below histopath image of subcutaneous panniculitic T cell lymphoma (SPTCL), one of the following is true:-



1. WHO-EORTC current classification divides it into two subtypes- $\alpha\beta$ and $\gamma\delta$
2. It can be easily differentiated from lupus profundus based on dense lymphocytic infiltrate
3. Confusion remains whether cytophagic histiocytic panniculitis and SPTCL are related or distinct entities
4. SPTCL on histopathology shows predominantly septal panniculitis with admixture of T and B lymphocytes

Q 14. A 24 year old man comes with complaint of recurrent eruption on face for 6 years. On examination, there are erythematous papules and nodules involving the forehead, cheeks, nose, eyelids and ear rim. Interspersed are numerous deep pitted scars. You have decided to go ahead with a skin biopsy. What do you expect to find?



1. Dense perifollicular lymphocytic and neutrophilic infiltrate with follicular spongiosis
2. Peri-follicular granulomas with caseation necrosis
3. Naked granulomas in upper and mid dermis
4. Mid dermal interstitial and peri-follicular granulomas

IMAGE CONTRIBUTORS:

Dr. Saurabh Singh (Associate Professor, Department of Dermatology, AIIMS Jodhpur)

Dr. Jyotsna Bharti (Associate Professor, Department of Pathology, AIIMS Jodhpur)

Dr. Ravi Mudugal (SR, Department of Dermatology, AIIMS Jodhpur)

Dr. Sahiba Rafi (2nd year MD student, Department of Dermatology, AIIMS Jodhpur)

Dr. Utkrist Lahoria (3rd year MD student, Department of Dermatology, AIIMS Jodhpur)

Poem



Dr Indu Kumari

*Consultant Dermatologist,
All India Skin and Hair hospital, Delhi*

An eye underneath

My early morning curious eyes
stare at lots of pinks and little blue.
Come on, I m not being gendered,
rather a dermatopathologist in true.
The day started like,
Spongiotic & spongiotic & spongiotic
a hide and seek with hyphae.
Be it insect bite or bullous pemphigoid,
little eosinophils, i must gratify.
Granulomas looked friendly till single
foamy cells and suppuration created all the fuzz.
What looked like lupus vulgaris was actually a chromo.
Mycetoma without grain, have you ever heard of?
Is it, Hidradenitis suppurativa or scrofuloderma,
Erythema induratum or nodosum
Hold on, hold on;
What I see is just folliculitis,
u accept it or not.
One year went off just in a fight
between eczema and psoriasis
& of course my heart and my mind.
Why, I mean why I was here
with aches in my head and
Strains in my eyes.
But something I saw which no one could,
multinucleate giant cells in the vesicle,
a hidden thrombus in fat globules.
My observations which were loud so far
became patient and keen.
You have two eyes, sir always say
one at the lesion and one underneath.
PS: Look at the process, not the individual cell
with all your acumen.

Tips for Obtaining Optimal Skin Biopsy Specimens in Inflammatory Dermatoses



Dr Geeti Khullar

Vardhman Mahavir college and Safdarjung hospital

Skin biopsy is the most common and essential procedure performed by dermatology residents. The size of biopsy, its depth, preferred site and type of lesion, number of specimens and timing in relation to disease evolution are critical determinants of the yield of skin biopsy sample. Some of these important points pertaining to specific dermatoses, that can impact the histopathological results and hence the diagnosis, are summarized below.

- 1. Alopecia-** The hair should be trimmed and not shaved at the site of biopsy. Two punch biopsies 4 mm or more in size should be taken, placing the punch along the direction of the hair growth to avoid transection of hair follicles. The biopsy should be deep enough to reach the subcutis to enable visualization of the hair bulbs. For scarring alopecia, sample should be taken from the active border of a well-developed lesion and not from the centre (scarred area), as the former will demonstrate the causative pathology. One specimen is bisected vertically- half is sent for hematoxylin-eosin staining and other half for direct immunofluorescence (DIF). The second specimen is sectioned horizontally. In case of non-scarring alopecia such as androgenetic alopecia, it is informative to obtain biopsy specimens from both the affected and control area (occiput). Both the specimens are submitted for horizontal sectioning.
- 2. Annular lesions-** Biopsy must be taken from the advancing border in granuloma annulare and porokeratosis.
- 3. Autoimmune bullous disorders-** If a small vesicle is present, the entire lesion is sampled. In case of larger bulla, specimen should be obtained from the edge so as to contain both the blister and the intact skin. Lower extremity should be avoided because of delayed healing and possibility of false negative results. In dermatitis herpetiformis, biopsy should be taken from a non-excoriated papule instead of a vesicle. Specimen for DIF is taken from the uninvolved perilesional skin within 1-2 cm from the bulla and transported in Michel's medium or normal saline. Inflamed skin and area too close to the blister is avoided as immune deposits are degraded, leading to false-negative results. Caution should be taken to avoid formalin contamination of DIF sample.
- 4. Epidermolysis bullosa-** Blisters older than 12 hours are not suitable for diagnosis because of false negative immunostaining due to antigen degradation, re-epithelialization under blister roof and multiple planes of cleavage. Therefore, a fresh blister is induced by gently rubbing with a cotton swab or pencil eraser on clinically uninvolved skin to produce mild erythema. Topical anesthetic should be avoided as it can induce artificial blister. The specimen is obtained 5 minutes after the development of erythema and must include the border of erythematous and normal looking skin. Sufficient amount of dermis should be included to examine the dermo-epidermal junction. The sample should be placed in 2% glutaraldehyde solution for electron microscopy and in Michel's medium for immunofluorescence.
- 5. Erythroderma-** Multiple skin biopsies taken simultaneously from different sites and over a period of time are often required as a specific etiologic diagnosis is made only 50% of the times.

6. **Leprosy**- A 4 mm punch biopsy including full thickness of the dermis and a portion of the subcutaneous fat should be obtained. In indeterminate leprosy, centre of the anesthetic lesion or border of an annular macule should be biopsied. In tuberculoid, borderline tuberculoid (BT) and mid-borderline leprosy, the biopsy must be from infiltrated margins. The centre of the macule, plaque or nodule is ideal for borderline lepromatous (BL) and lepromatous leprosy. In case of BT downgrading to BL, biopsies should be obtained from representative lesions of both types of leprosy.
7. **Mastocytosis**- Anesthetic agent without epinephrine should be injected around the lesion and not directly into the lesion to avoid mast cell degranulation. Trauma during handling of biopsy should be minimized.
8. **Nail biopsy**- A small punch biopsy of 3 mm is enough to visualize the nail plate or nail bed. A two punch method may also be used, where a larger punch is used to remove the nail plate and then smaller punch is used for nail bed or nail matrix. A tourniquet is applied before the biopsy and ring block anesthesia is given.
9. **Panniculitis**- A deep incisional biopsy should be taken from an early lesion as late stage lesion may give rise to non-specific findings. Sometimes more than one biopsy may be required from lesions in different stages of evolution to improve the diagnostic yield as the composition and distribution of infiltrate evolve over time.
10. **Vasculitis**- The biopsy should be taken from a purpuric lesion present for less than 48 hours in cutaneous small vessel vasculitis. For suspected medium vessel vasculitis, a deep incisional biopsy should be performed from the nodule. For livedo lesions, it is taken from the pale centre and in ulcers, from the trailing edge of the ulcer. If considering IgA vasculitis, sample for DIF should be obtained from a lesion less than 24 hours old.
11. **Vitiligo**- Biopsies should be taken from both lesional and uninvolved perilesional skin for comparison.

References

1. Elston DM, Stratman EJ, Miller SJ. Skin biopsy: Biopsy issues in specific diseases. *J Am Acad Dermatol*. 2016;74:1-16.
2. Khopkar U, Doshi B. Improving diagnostic yield of punch biopsies of the skin. *Indian J Dermatol Venereol Leprol*. 2008;74:527-31.
3. Massone C, Belachew WA, Schettini A. Histopathology of the lepromatous skin biopsy. *Clin Dermatol*. 2015;33:38-45.

Summary of a published article

Cutaneous protothecosis in an immunocompetent host



Dr. Aswath Rajan

Senior resident, Department of Dermatology
Goa Medical college, Goa.

Other Contributors

Dr. Varadraj Vasant Pai

Department of Dermatology
Goa Medical college, Goa.

The Prototheca species are achlorophyllic algae that do not possess chloroplast or pyrenoids and behave as saprophytes.¹ *P. wickerhamii* and *P. zopfii* are the species reported to cause infections in humans, with *P. wickerhamii* being more common of the two.² More than 160 cases of protothecosis have been reported worldwide predominantly in immunocompromised patients, with one case of disseminated protothecosis reported from India.^{3,4} We report a case of cutaneous protothecosis in an immunocompetent host.

A 69-year-old male farmer, presented with a three-month history of an asymptomatic lesion over the right forearm, which was accidentally detected when the patient was admitted for furosemide-induced hypersensitivity syndrome, which was treated symptomatically without systemic corticosteroids. History of contact with soil, plants and trees with bare hands and recurrent trauma secondary to it was noted.

Clinical cutaneous examination revealed a well-defined plaque with an irregular border, measuring 5 × 3 cm, over the extensor aspect of the right forearm. The surface was studded by skin-colored to hyperpigmented papules, few isolated and few coalesced to form a reticulate network with areas of intermittent atrophy and scarring with few satellite lesions. The differential diagnosis considered were atrophoderma vermiculatum, keratosis pilaris atrophicans and anetoderma. [Figure 1] Dermoscopy of the lesion showed a distorted pigment network, whitish areas suggestive of fibrosis, clusters of yellowish-brown globules and multiple pinkish structureless areas. [Figure 2]

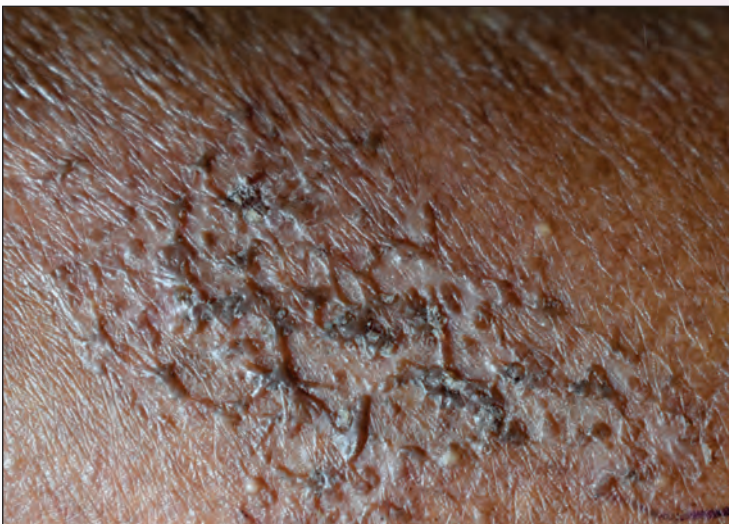

Figure 1: Hyperpigmented papules in a reticulate network, with areas of intermittent atrophy




Figure 2: Dermoscopy showing a distorted pigment network (blue arrow), whitish areas suggestive of fibrosis (red arrow), clusters of yellowish-brown globules (black arrow) and multiple pinkish structureless areas (HEINE DELTA 20T Dermoscope, polarised light 10x)

Histopathological examination of the lesion showed that the upper and mid dermis had a band-like diffuse infiltrate of histiocytes with abundant cytoplasm surrounded by focally dense lymphoplasmocytic infiltrate with several eosinophils. On periodic acid Schiff (PAS) staining, numerous PAS positive bodies packed together forming a symmetrical morula or cartwheel-like structure were seen within the histiocytes. Therefore, a diagnosis of cutaneous protothecosis was made. [Figures 3,4 and 5].

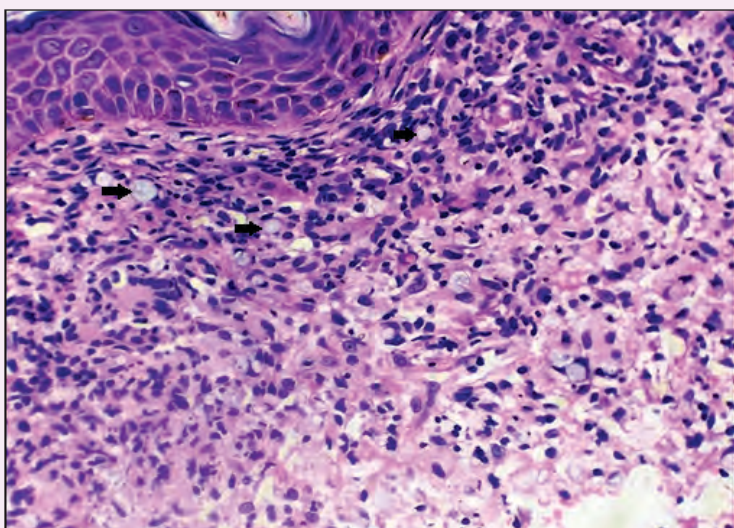


Figure 3: Histopathological image showing Band like diffuse infiltrate of histiocytes with abundant cytoplasm, with morula-like structures (black arrow) surrounded by focally dense lymphoplasmacytic infiltrate with several eosinophils (H and E, $\times 400$)

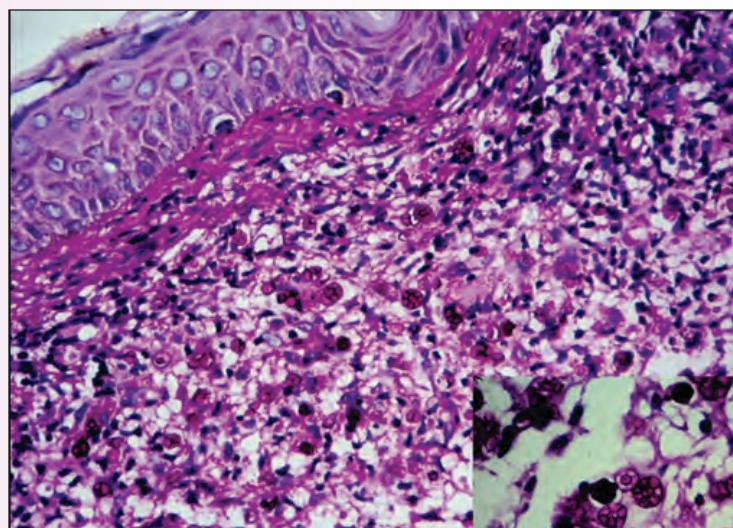


Figure 4: Periodic acid Schiff (PAS) stain with numerous PAS-positive bodies packed together forming morula or cartwheel-like structures, seen within the histiocytes (PAS, $\times 400$). Inset – symmetrical morula like structures as seen in *Prototheca wickerhamii* (Histopathology picture $\times 1000$)

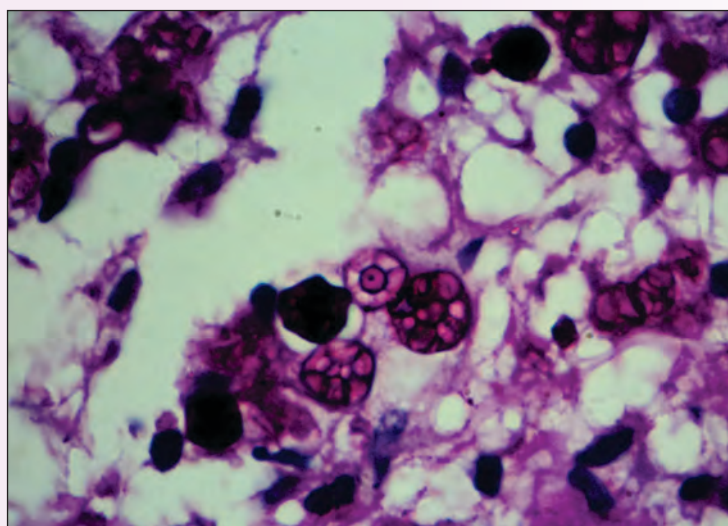


Figure 5: Periodic acid Schiff (PAS) stain (histopathology picture $\times 1000$) with symmetrical cart-wheel morula like structure suggestive of *Prototheca wickerhamii*

The patient was treated with tablet itraconazole 200 mg twice a day for 3 months. He showed significant improvement at the end of 3 months and was later lost to follow up [Figures 6 and 7].

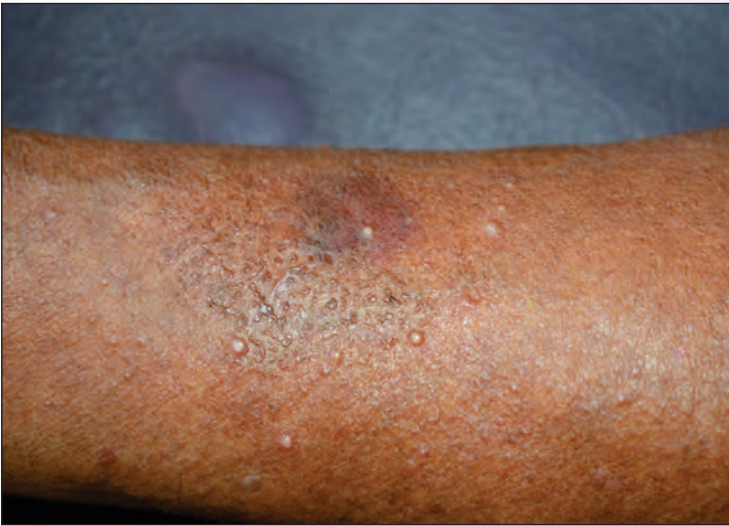

Figure 6: Lesion on the right forearm showing significant improvement with 3 months of treatment

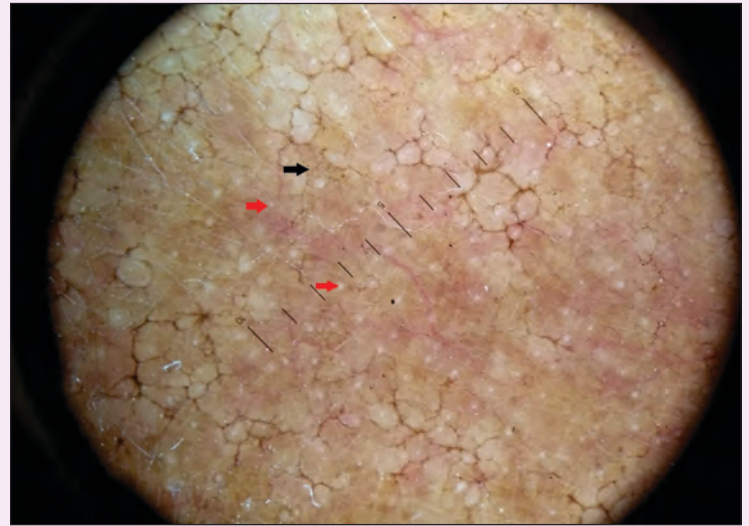


Figure 7: Dermoscopy of the lesion after 3 months treatment with itraconazole, showing reduced yellowish-brown globules, reduced white areas (fibrosis), reappearance of reticular lines (black arrow) and ductal opening (red arrow).

Acknowledgement

Thanks to Dr Rajiv Joshi for the histopathological analysis and pictures.

Permission for publication was obtained from IJDVL Editor

References:

1. Seok JY, Lee Y, Lee H, Yi SY, Oh HE, Song JS. Human cutaneous protothecosis: Report of a case and literature review. *Korean J Pathol* 2013;47:575-8.
2. Lu S, Xi L, QinW, LuoY, LuC, Li X. Cutaneous protothecosis: Two new cases in China and literature review. *Int J Dermatol* 2012;51:328-31
3. Todd JR, King JW, Oberle A, Matsumoto T, Odaka Y, Fowler M, et al. Protothecosis: Report of a case with 20-year follow-up, and review of previously published cases. *Med Mycol* 2012;50:673-89.9
4. Mathew LG, Pulimood S, Thomas M, Acharya MA, Raj PM, Mathews MS. Disseminated protothecosis. *Indian J Pediatr* 2010;77:198-9

Review article

Deep learning in dermatopathology: Present scenario and future



Dr. Satarupa Kumar

Post graduate resident, Department of Dermatolog

III Year Resident, MD DVL Medical College Kolkata

Artificial intelligence (AI) is a branch of computer science that uses machines and programs to simulate intelligent human behavior. **Machine Learning (ML)** is a tool that enables the goals of artificial intelligence to be achieved.

Deep learning (DL) is a subset of ML that uses statistical and mathematical models to mimic how neurons process information. Artificial intelligence, and specifically deep learning, is now being applied to the fields of clinical dermatology and dermatopathology alike since both specialties are image intense, rely on the integration of visual skills for diagnosis, and are a natural segue for algorithmic development.

Today, deep learning is the method of choice to solve tasks related to histopathology data, such as segmentation, classification of individual cells and prediction of clinical variables from the tissue slide. A number of DL models have been proposed in the context of computational pathology that are traditionally based on convolutional neural networks (CNNs), recurrent neural networks (RNNs), generative adversarial networks (GANs), auto-encoders (AEs) and other variants.¹

The introduction of whole slide scanners in the 1990s made it much easier to produce digitized images of whole tissue slides at microscopic resolution, and this has triggered the development of complex DL models in computational histopathology. Whole-slide images (WSIs) allow entire high-resolution slides to be stored permanently in a digital format, making it easier to classify these images using an algorithm. In April 2017, the US FDA approved the first whole slide scanner system for use in primary diagnosis.² While most studies have focused on using CNNs to classify WSIs, one study has reported that basal cell carcinoma can also be identified by using microscopic ocular images (MOIs) of histopathological tissue sections.³ MOIs are images taken on a smartphone equipped with a microscope eyepiece.

Convolutional neural networks use a data-driven approach to automatically learn feature representations for images, achieving super-human performance on benchmark image classification datasets. A neural network (NN) draws on similarities from interconnected biological neurons and is structured in such a way so as to learn and improve on its performance, based on how many images the CNN “sees” and the amount of convolutions (combined inputs of two images, a new one and an existing catalogued image, to create a third output) the CNN generates.⁴ An image can be broken down into motifs, or a collection of pixels that form a basic unit of analysis. The first few layers of the CNN compare each part of an input image against some small sub-image. Each node is assigned a certain feature (e.g., color, shape, size, etc.), and the node's output to the next layer depends on how much a part of the image resembles the feature, a process performed by convolution. After these convolutional layers, pooling layers, which are a standard NN, classify the overall image. CNNs first showed promise for medical image classification at the historic 2012 ImageNet Large Scale Visual Recognition conference. A CNN, called AlexNet, was trained to classify 1.2 million images into 1000 different categories with a top-5 error rate of 15.3%, which is the percentage of images for which the correct class was not among the top five predicted classes. This was the first CNN to display such a low error rate.⁵ CNNs are the current state-of-the-art architecture for medical image analysis.

Approaches:

Traditionally, there have been two fundamentally different ML approaches in digital pathology image analysis.⁶

Supervised learning: It requires a dataset to be presented as inputs (called features) and outputs (called labels). The goal of supervised learning is to infer a function that can map the input images to their appropriate labels (e.g. cancer) using training data. Labels are associated with a WSI or an object in WSIs. The learned model is then applied to an unseen test set and the method is validated based on how successful it was in assigning test data to different classes.

The disadvantage of supervised learning techniques is that they are limited to learning from labeled datasets which are often expensive, time consuming, or difficult to generate. If the available labeled dataset is too small and does not represent the true variance of the data space then generalization performance may be poor. High quality datasets requires the effort of experienced and trained human observers.

Unsupervised learning: On the other side of the spectrum are the unsupervised learning methods which only requires inputs (unlabeled data). These unlabeled data points are grouped into clusters that share similar properties. The tasks include clustering, anomaly detection and dimensionality reduction. Unlabeled datasets are often easier to acquire and require less human effort to create since it does not require the input of a clinician to label images for training the model, however, since the information provided to these techniques is unlabeled, there is no clear way to validate the quality of this approach.

There are derivatives from these two learning such as semi-supervised learning and transfer learning.

In contrast to supervised learning, which only considers labeled data, and unsupervised learning which works only on unlabeled data, **semi-supervised learning** (SSL) methods work with both labeled and unlabeled data points. Unlabeled data is used to estimate the true distribution of labeled data. Therefore, by using SSL, it is possible to combine the advantages of working with a small labeled dataset to guide the learning process and a larger unlabeled dataset to increase the generalizability of the found solution.⁶

The most popular and widely adopted technique in digital pathology is the use of **transfer learning** approach.(Fig.1.) Here, the goal is to extract knowledge from one domain (i.e., source) and apply it to another domain (i.e., target) by relaxing the assumption that the train and test set must be independent and identically distributed.¹ It utilizes the power of a pretrained CNN. These pretrained CNNs are often trained on databases that include millions of images, so they are able to distinguish images with much higher accuracy than a CNN that is only trained on databases of only a few hundred. The last fully connected

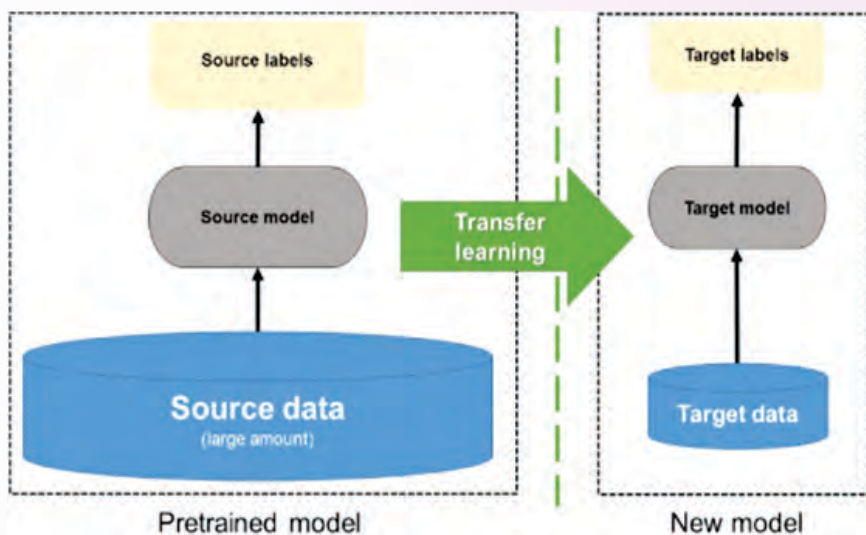


Fig 1. Illustration of Transfer learning.

Taken from Chaves E, Gonçalves C, Albertini M, Lee S, Jeon G, Fernandes H. Evaluation of transfer learning of pre-trained CNNs applied to breast cancer detection on infrared images. *Appl. Opt.* 59, E23-E28 (2020).

layer of a pretrained CNN is modified and trained with images for the more specific classification task. The learning process of a pretrained CNN can be faster because it relies on previously learned tasks. Using a pretrained CNN that is trained on 1–2 million images is more accurate than a CNN that is trained on a smaller number of images of the more specific classification tasks.

Does it provide an edge over traditional histopathological slide analysis by dermatopathologists?

Since dermatopathology is an image-intense subspecialty and low-power recognition is often an important first step for accurate diagnosis, application of DL algorithms to cutaneous WSI allows for computer-assisted diagnosis. It can be employed to recognize morphological patterns within the specimen for diagnostic and triaging purposes and development of quantitative profiles informative about disease status and prognosis.

However, dermatopathologists remain critical for rendering a final and accurate diagnosis. Areas of high inter-pathologist discordance and rising biopsy rates necessitate higher efficiency and diagnostic reproducibility. Automated image analysis through machine learning will ultimately decrease the workload of pathologists, reduce turnaround times for reporting, standardize clinical practices and may result in improved workflow efficiencies for dermatopathologists and laboratories.

DL system will serve as a foundation enabling faster diagnosis of skin cancer, identification of cases for specialist review, and targeted diagnostic classifications.

Survival models can be trained using ML techniques that can either generate a probability of an event in a certain predefined period of time, or can predict time to an event using regression from a WSI. In the context of skin cancer, the term prognosis refers to the likely outcome for a patient on standard treatment, and the term prediction refers to how the patient responds to a particular treatment.¹

Position in dermatopathology:

The complexity of examining histopathology was first captured in one study that developed a framework for an unsupervised model to identify learned features of basal cell carcinoma histopathology. However, with this approach, explanations for why certain patterns and features chosen by the algorithm that discriminate between cancer and healthy tissue were not always apparent. In some cases, patterns discovered that are thought to be specific for cancer actually identify cell proliferation patterns seen in healthy tissue. Therefore, more recent studies have relied on supervised learning, in which a dermatopathologist labels images to help train the model. Models trained with image curation done by a dermatopathologist were found to be 50% more accurate and to take significantly less time to train.⁶

Most ML methods used to classify histopathology have focused on skin cancer, but there are early studies working on classifying other diseases. CNN can differentiate dermis from epidermis in the histopathology of psoriasis lesions.⁷ This is the first step toward developing a ML solution for automatic segmentation and diagnosis of psoriasis pathology. Further research will need to go beyond this basic segmentation and find more specific features, such as detecting changes in the epidermis and the presence of immune cells.

A team of U.S. researchers accurately trained a CNN to classify three common dermatopathology diagnoses, according to recent research. WSI of previously diagnosed nodular basal cell carcinomas, dermal nevi, and seborrheic keratoses were annotated for areas of distinct morphology. A proprietary CNN was used to train algorithms to classify test images as positive or negative relative to ground truth diagnosis.⁸

Ianni et al. formulated a pathology deep learning system (PDLS) which is capable of classifying WSIs containin skin biopsies or excisions into diagnostically-relevant classes (Basaloid, Squamous, Melanocytic and Other). While the PDLS does not make

diagnostic predictions, its classification may increase diagnostic efficiency and consistency in several scenarios. For example, dermatopathologists might choose to prioritize certain classes, e.g. Melanocytic, that may require longer review time, or ancillary testing such as immunostains. Similarly, a dermatologist who interprets biopsies could choose to only receive cases classified as Basaloid, and refer other cases.⁹

Challenges:

While ML methods are powerful, physician interpretation is crucial for their implementation in a real-world setting. The main challenges in transforming AI technologies from research to clinical use are as follows.

- ❖ First, is the availability of labeled training data and regulatory concern in getting ownership of the histopathological data. This makes it challenging to train, develop and test safe AI solutions for clinical use.
- ❖ Most DL methods in digital pathology are applied on small-sized image patches rather than the entire WSI, restricting the prediction ability of the model to a narrow field of view. Also, a large number of redundant computations are carried out in overlapping regions, resulting in increased computational complexity and slower inference speed. To address the former issue, attempts have been made to mimic the way in which a pathologist usually analyzes a slide at various magnification levels before arriving at the final decision.¹
- ❖ Most AI algorithms suffer from inapplicability outside of the training domain, algorithmic bias and can be easily fooled by adversarial attacks or by the inclusion of disease subtypes not considered during training. These issues can be partly addressed by developing “interpretable” AI systems which provide a reliable measure of model confidence and also generalization to different multi-cohort datasets.¹
- ❖ One must also be cognizant of how potential biases can interfere with the black box nature of these algorithms (models that do not explain their predictions in a way that humans can understand). Developing human-centred AI models that can meaningfully represent clinical knowledge and provide a clear explanation for model prediction is of paramount importance to facilitate improved interactions with clinicians.
- ❖ WSIs are multigigabyte images with typical resolutions of 100000×100000 pixels, present high morphological variance and often contain various types of artifacts. Inability of the current state of the hardware to facilitate learning from images with such high resolution (thereby reducing some form of dimensionality reduction to the images) and visual understanding of the images, impeded by artifacts, morphological variance and typically small data sets preclude the direct application of conventional DL techniques.¹⁰
- ❖ In actual diagnostic situations, unexpected objects such as aberrant organization, rare tumor (thus not included in training data) and foreign bodies could exist. However, discrimination model including CNNs forcibly categorizes such objects into one of the pre-defined categories. To solve the problem, outlier detection algorithms, such as one-class kernel principal component analysis, have been applied to the digital pathological images but only a few researches have addressed the problem so far.⁶

If the above challenges are taken into consideration while designing AI solutions, then they are most likely to be transformational in routine patient health care system.

Conclusion:

The combined effect of the introduction of deep learning, the democratization of powerful graphics processing unit (GPU) computing capacity, and increasing use of digital pathology has created an unprecedented opportunity to explore the power of machine learning in dermatopathology. The ability of CNNs to learn features directly from the raw data without the need for specialist input from pathologists and the availability of annotated histopathology datasets has fueled the interest in deep learning applied to histopathology. Dermatopathology, with emphasis on pattern recognition, offers a unique opportunity for testing deep learning algorithms. Though still in its infancy and hurdled with certain challenges, successful application of deep learning to WSIs has the potential to create new clinical tools that will surpass current clinical approaches in terms of accuracy, reproducibility and objectivity while also providing novel insights on various pathologies of the skin.

Conflicts of interest: None

References:

1. Srinidhi C, Ciga O, Martel A, 2020. Deep Neural Network Models For Computational Histopathology: A Survey. [online] arXiv.org. Available at: <<https://arxiv.org/abs/1912.12378>> [Accessed 15 August 2020].
2. U.S. Food and Drug Administration. 2020. FDA Allows Marketing Of First Whole Slide Imaging System For Digital Pathology. [online] Available at: <<https://www.fda.gov/news-events/press-announcements/fda-allows-marketing-first-whole-slide-imaging-system-digital-pathology>> [Accessed 15 August 2020].
3. Jiang YQ, Xiong JH, Li HY et al. Recognizing basal cell carcinoma on smartphone-captured digital histopathology images with a deep neural network. *Br J Dermatol.* 2019;182:754–62.
4. Dermnetnz.org. 2020. Convolutional Neural Networks In Dermatology | Dermnet NZ. [online] Available at: <<https://dermnetnz.org/topics/convolutional-neural-networks-in-dermatology/>> [Accessed 15 August 2020].
5. Chan S, Reddy V, Myers B, Thibodeaux Q, Brownstone N, Liao W, 2020. Machine Learning in Dermatology: Current Applications, Opportunities, and Limitations. *Dermatology and Therapy*, 10(3), pp.365-386.
6. Komura D, Ishikawa S, 2018. Machine Learning Methods for Histopathological Image Analysis. *Computational and Structural Biotechnology Journal*, 16, pp.34-42.
7. Pal A, Garain U, Chandra A, Chatterjee R, Senapati S. Psoriasis skin biopsy image segmentation using Deep Convolutional Neural Network. *Comput Methods Programs Biomed.* 2018;159:59–69.
8. Kent M, Olsen T, Jackson B, Feeser T, Moad J, Krishnamurthy S, Lunsford D, Soans, R., 2018. Diagnostic performance of deep learning algorithms applied to three common diagnoses in dermatopathology. *Journal of Pathology Informatics*, 9(1), p.32.
9. Ianni J, Soans R, Sankarapandian S, Chamarthi R, Ayyagari D, Olsen T, Bonham M et al., 2020. Tailored For Real-World: A Whole Slide Image Classification System Validated On Uncurated Multi-Site Data Emulating The Prospective Pathology Workload.
10. Dimitriou N, Arandjelović O, Caie P, 2019. Deep Learning for Whole Slide Image Analysis: An Overview. *Frontiers in Medicine*, 6.

"Dermatopathology" in "La La land"



Dr. Divyal D. Gala

*Consultant Dermatologist
Shanti Nursing Home, Mumbai*

I, Dr. Divyal D. Gala from Mumbai, completed MD in Dermatology from Rajawadi Hospital, Mumbai. At the very beginning of the residency, dermatopathology was an essential part of the curriculum. I am grateful to my Mentor Dr. Nitin J. Nadkarni for all the efforts he took to make dermatopathology an interesting subject. After completing MD, I was always interested to learn dermatopathology more and searched training programmes for the same.

In January 2019, I got an opportunity to learn the subject at David Geffen School of Medicine, University of California (UCLA), Los Angeles. I had applied for 3 months Observership, but during that period they offered me 8 weeks (Jan-March) of Observership in Dermatopathology. Usually, they conduct 1-2 year fellowship courses. I had applied to International Physician Observership Programme- IntlEdu@mednet.ucla.edu. Tuition fee was waived off. Travelling and accommodation was excluded. David Geffen School of Medicine is located in Westwood, Los Angeles. I stayed at Culver City.

I did my Observership under Dr. G. Peter Sarantopoulos.

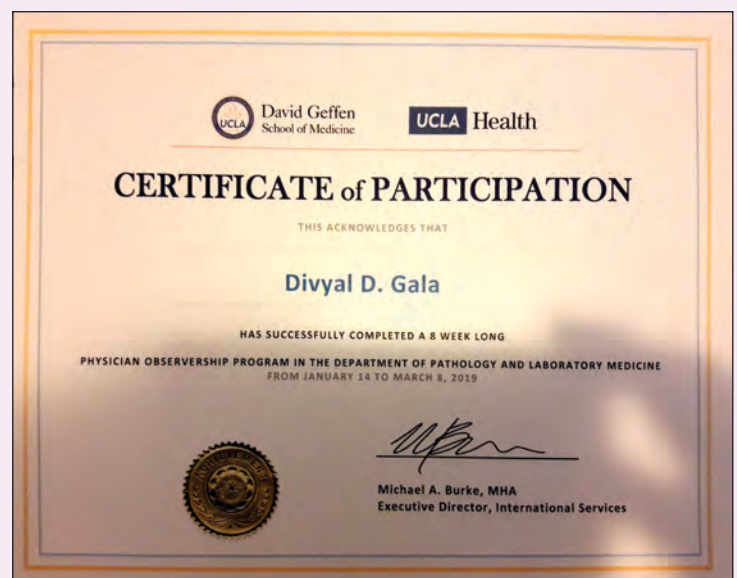Apart from slide discussion, every Monday, they conducted Noon conference and Wednesday, there was Weeden lecture.

I also got an opportunity to attend Grand Clinical Rounds every Tuesday at Ronald Reagan Hospital.


Slide discussion mainly included:

- 1) Seborrhic Keratosis
- 2) Nevi- Junctional, compound, intradermal
- 3) Dysplastic nevi
- 4) Melanoma
- 5) Mycosis fungoides
- 6) Squamous cell carcinoma
- 7) Basal cell carcinoma
- 8) Adnexal malignant tumours.

Overall the experience was enriching. Los Angeles well known as La La land is a beautiful place and UCLA campus is mesmerizing.



Answer to the crossword



Created using the Crossword Maker on TheTeachersCorner.net

Across

1. pieces of the puzzle on the turban snuggle (jigsaw)
5. fence around the collection of life and death (palisade)
8. Reminiscent of graveyards, in a grave bullous disease (tombstone)
9. behold ye diamonds in a red 'glance' (lozenge)
10. pretty french 'round bodies' amidst the dirty warty ones (corns)
12. garland of flowers you find in this fatty giant (touton)
13. pus adorns psora's horn (munro)
16. atypical cells between the bundles, 'one at a time' (5,4) (indian file)
17. like bulbs around a mirror, the bodies appear (marquee)
19. burning bright in wells figures are swell (flame)
20. strawmats and whorls in tumour benign (storiform)

Down

2. celestial bodies, link naked collections to rose thorns (asteroid)
3. radiating around emptiness within the nodules subcutaneous (miescher)
4. stacked like yellow grains on their cob (cornoid)
6. its flying away in complete disarray (windblown)
7. tilted tier in horny layer, thus the collarette appear (teapot lid)
8. army of odd blue ones, summoned to base (3,7) (toysoldier)
11. trilayered inside the porcelain-white dells (striped)
14. tumours of dermis zoned clear of epidermis (grenz)
15. clubbed like the hoofs of desert's brute (5,4) (camel foot)
18. sign so 'dear' when lacy pigmentation in flexures appear (antler)

Answer Quiz 1 & 2

Answer to Quiz: 1

1(B),
2(D),
3(A),
4(A),
5(D),
6(D),
7(D),
8(D),
9(D),
10 (C),
11(B),
12(A),
13(D),
14(D),
15(A),
16(A),
17(B),
18(D),
19(D)

Answer to Quiz : 2

1.(2)
2.(3)
3.(4)
4.(4)
5.(3)
6.(4)
7.(2)
8.(2)
9.(4)
10.(3)
11.(3)
12.(4)
13.(3)
14.(2)

IADVL Office Bearers

IADVL ACADEMY - 2020

Chairperson (2020-21): Dr. Deepika Pandhi **Convener (2020-21):** Dr. Dipankar De

EX-OFFICIO MEMBERS

Dr. Kiran Godse (President)	Dr P. Narasimha Rao (Imm.Past President)
Dr Jayadev Betkerur (President Elect)	Dr Feroz K (Hon. Secretary General)
Dr Rakhesh SV (Hon. Treasurer)	Dr Umashankar Nagaraju (Imm. Past Hon. Secretary General)
Dr Seetharam KA (Imm. Past Academy Chairperson)	Dr Shashikumar BM ((Imm. Past Hon. Treasurer)
Dr. Sunil Dogra (Editor, IDOJ)	Dr. Saumya Panda (Editor, IJDVL)

MEMBERS

Dr Ananta Khurana	Dr G. Manmohan	Dr Kanthraj GR	Dr Krishna Talukdar
Dr Meghana M Phiske	Dr Nilay Kanti Das	Dr Renu George	Dr Raghunatha S
Dr Rashmi Jindal	Dr Santoshdev P. Rathod	Dr Sumit Sen	Dr Usha Khemani

IADVL

PRESIDENT
Dr. Kiran Godse

IMM. PAST PRESIDENT
Dr. P. Narasimha Rao

PRESIDENT ELECT
Dr Jayadev Betkerur

VICE PRESIDENTS
Dr. Manjunath Shenoy Dr. Rashmikant Shah

HON GEN SECRETARY
Dr. Feroze K.

HON. TREASURER
Dr. Rakhesh SV

HON JOINT SECRETARY
Dr. Konakanchi Venkatachalam Dr. Anuradha K Babu

Design & Layout by :



CBS Publishers & Distributors Pvt. Ltd.

Dedicated to Education

Branches : New Delhi · Bengaluru · Chennai · Kochi · Kolkata · Mumbai

Resident Rep. : · Bhubaneswar · Dehradun (UttaraKhand) · Giridih (Jharkhand) · Hyderabad · Nagpur · Patna · Pune · Vijayawada

www.cbspd.com