

Platelet-Rich Plasma in Androgenetic Alopecia

Abstract

The goal of these recommendations is to provide a framework to practitioners for implementing useful, evidence-based recommendations for the preparation of platelet-rich plasma (PRP) and its use in androgenetic alopecia (AGA). The Indian Association of Dermatologists, Venereologists and Leprologists (IADVL) assigned the task of preparing these recommendations to its taskforce on PRP. A comprehensive literature search was done in the English language on the PRP across multiple databases. The grade of evidence and strength of recommendation were evaluated on the GRADE (Grading of Recommendation, Assessment, Development, and Evaluation) framework. A draft of clinical recommendations was developed on the best available evidence, which was also scrutinized and critically evaluated by the IADVL Academy of Dermatology. Based on the inputs received, the final consensus statement was prepared. A total of 30 articles (meta-analyses, prospective and retrospective studies, reviews [including chapters in books], and case series) were critically evaluated, and the evidence thus gathered was used in the preparation of these recommendations. This expert group recommends use of manual double-spin method for the preparation of PRP for AGA. Minimum three to five sessions of PRP are recommended for AGA with a gap of 1 month between the two sessions. Patients with Grade II to V Norwood Hamilton classification of AGA are the ideal subset for PRP. A total of 5 to 7 mL of PRP and 0.05 to 0.1 mL/cm² is the recommended dose of PRP for AGA. Activation of PRP is not required when it is used for AGA. About 1 to 1.5 million platelets/ μ L of platelets in PRP is the recommended platelet concentration in PRP for the treatment of AGA. I-PRF (injectable platelet-rich fibrin) has also been found to be useful in AGA, although further studies are required to establish its role. PRP can also have an adjunctive role in hair transplantation procedures.

Keywords: *Androgenetic alopecia, hair transplant, male pattern baldness, PDO, platelet-rich plasma, platelet-rich plasma guidelines, preparation, RCF, recommendations, regenerative medicine, RPM, threads*

Introduction

Platelet-rich plasma, abbreviated as PRP, has come a long, long way in the past three decades. What began as a humble platelet concentrate for correcting thrombocytopenia in the 1970s has now forayed into the field of aesthetic medicine and therein has created quite a stir. And while the indications range from clinical to functional to cosmetic, PRP has faced quite some opposition.^[1]

From the inception of the first platelet concentrate in the 1950s to being used as an adjunct to make bony particles sticky in oral maxillofacial surgeries, PRP has been riddled with controversy.^[1] There are clearly defined schools of thought when it comes

to PRP, and this dichotomy stems from the fact that the methodology is variable, and not standardized. In fact, as of date, we are yet to have a clear set of guidelines on how to make PRP.^[2] What ensues from improper methodology is “inadequate” PRP, and hence a negative skewing of opinion and data. Simply put, it leads operators to believe that PRP does not work, even when their own preparation has not been controlled, tested, and quantified, in terms of platelet concentration. Very limited literature remarks on the final preinjection yield of PRP, and how it was calculated, and whether the yield actually achieved an angiogenic potential.

By definition, PRP, as a fraction of whole blood, must contain more than fourfold

This is an open access journal, and articles are distributed under the terms of the Creative Commons Attribution-NonCommercial-ShareAlike 4.0 License, which allows others to remix, tweak, and build upon the work non-commercially, as long as appropriate credit is given and the new creations are licensed under the identical terms.

For reprints contact: WKHLRPMedknow_reprints@wolterskluwer.com

How to cite this article: Sharma A, Chouhan K, Bhatia S, Dashore S. Platelet-rich plasma in androgenetic alopecia. *Indian Dermatol Online J* 2021;12:S31-40.

Received: 25-May-2021. **Revised:** 13-Jun-2021.
Accepted: 21-Jul-2021. **Published:** 25-Nov-2021.

**Aseem Sharma,
Kavish Chouhan¹,
Satish Bhatia²,
Shuken Dashore³**

Chief Dermatologist, Skin Saga Centre for Dermatology, Mumbai, Maharashtra, ¹Director and Consultant Dermatologist, DERMACLINIX, New Delhi, ²Director and Consultant Dermatologist, DERMETICS, Mumbai, Maharashtra, ³Consultant Dermatologist, DHL Skin Centre, Indore, Madhya Pradesh, India

Address for correspondence:

*Dr. Aseem Sharma,
Chief Dermatologist, Skin Saga Centre for Dermatology, Andheri West - 400 053, Mumbai, Maharashtra, India.
E-mail: aseemsharma082@gmail.com*

Access this article online

Website: www.idoj.in

DOI: 10.4103/idoj.idoj_328_21

Quick Response Code:



of the baseline platelet count, or an absolute count of 1,000,000/mL in 5 mL PRP.^[3] A study by Dhurat *et al.*^[4] in 2014 standardized these guidelines, via the method of repetitive hit, trial, and error. Various factors discussed in this landmark article were shown to affect the final outcome of PRP and how to go about it. Factors ranged from, but not limited to, the volume of whole blood drawn to the volume of PRP injected, temperature control, centrifugation settings and calibration, the method of PRP, whether commercial kit was used or not, the type of anticoagulant used, and whether or not exogenous activation was performed. But since most studies follow alternative methods and materials to prepare PRP, the results show a very high variance. And this interindividual variability and operator dependency is what holds back PRP – not PRP itself, which poses the greatest challenge in this field.

PRP has often been touted as an elixir, not only in nonvalidated literature and on the internet but also in PubMed-indexed articles.^[5-7] Its indications range from aesthetic indications such as alopecias (androgenetic alopecia [AGA], alopecia areata, telogen effluvium, cicatricial), facial rejuvenation, acne scars, antiaging to clinical indications such as wound healing, lipodermatosclerosis, morphea, and lichen sclerosus. All the aforesaid indications are off-label, meaning that the treating physician can use this at his or her own discretion for a said indication as it is U.S. Food and Drug Administration (FDA) approved for another indication. Off-label usage is not new for us, dermatologists, both clinically and in the field of aesthetic medicine.

The earliest attempt to classify PRP was made by Anitua^[8] in 1999, which was only dependent on the crude platelet concentration. This was built on by Sánchez *et al.*^[9] in 2007 with red blood and white blood cell concentrations being considered for classification. Dohan Ehrenfest *et al.*^[10] in 2009, gave us the classification we know so very well – the pure or leukocyte-poor plasma and fibrin (P-PRP and P-PRF) and the leukocyte-poor plasma and fibrin (L-PRP and L-PRF).

PRP itself has undergone a generational change. PRP is the first-generation concentrate, whose growth factors (GFs) have a short life, ranging from minutes to an hour. The second-generation concentrates, whose prototype is platelet-rich fibrin (PRF) make use of the fact that platelets have a life of 7 to 10 days. Fibrin scaffolding helps in utilizing this property by causing a sustained release of GFs. And this scaffolding is achieved by not using an anticoagulant, but using a single-spin method in specialized tubes. Herein, we have the newer forms of PRP, which are as follows:

- a. A-PRF (advanced) – Monocyte-rich PRF
- b. I-PRF (injectable)
- c. CGF (concentrated GFs)
- d. HAS – Hyperacute serum
- e. T-PRF (titanium-activated)

With regard to efficiency, there is enough evidence to support the use of PRP in the fields of hair restoration and facial rejuvenation, with the limiting factor being an inefficient methodology for preparing and delivering PRP. The author reviewed the literature on Medline pertaining to the indications, as mentioned, and included only the highest levels of evidence, in this write-up.

Current concepts in AGA

PRP is used in AGA, as it possesses a plethora of GFs, and is mitogenic, angiogenic, and chemotactic for keratinocytes, melanocytes, and fibroblasts. Therefore, it acts on various pathways of the “Golden Anchorage” model of the hair follicle as proposed by Garg and Manchanda^[5] – the bulge, dermal papilla (DP), vasculature, and neural/signaling cells, thus stimulating hair growth, and regrowth of a total of 16 randomized controlled trials (RCTs) were meta-analyzed by Giordano *et al.*,^[11] wherein the pooled data showed an increase in hair diameter and hair count from the baseline. The results were not statistically significant. They also mentioned that there was a “high diversity in the method used in pooled studies.” Another meta-analysis by Dervishi *et al.*^[12] identified 13 relevant RCTs with 356 pooled patients with AGA, wherein a half-head study was done on PRP and found an increase in hair diameter as compared with placebo. Yet another randomized, double-blinded, active-controlled, split-scalp study by Gentile *et al.*^[13] recruited 23 patients and showed significant hair regrowth in AGA using PRP. A study by Qu *et al.*^[14] recruited patients with male and female pattern hair loss (FPHL) and concluded that PRP was effective in treating both conditions, while also improving hair texture, reducing seborrhea and inflammation, other pathomechanisms for progression of AGA. They also recommended that PRP worked best for lower grades of alopecia, namely, Grades II–III Norwood Hamilton for AGA, and Grades I–II Sinclair for FPHL. In total, 23 RCTs were explored by the authors wherein PRP was used in AGA. Of these, six trials (26%) were of high quality (active-controlled, half-head or split-scalp, independent evaluators). Seven trials (30%) were moderate in quality, which were placebo controlled and limited by the lack of independent evaluation, and 10 (44%) were of low quality.

There exists a significant need gap when we treat patterned alopecias. The FDA-approved therapeutic armamentarium is limited to topical minoxidil and oral finasteride. Low-level light and laser therapy have recently been cleared for safety by the FDA but are yet to be established as efficacious treatments. Minoxidil offers a modest treatment response as per Cochrane reviews with 40% to 50% patients deemed as nonresponders. The causes for the latter include low sulfation due to deficient or downregulated follicular sulfotransferase levels. Finasteride, though proven effective, is marred by low patient compliance owing to the hyped postfinasteride syndrome. Recently, even its role in

reversing miniaturization of the hair follicles has also been questioned.^[15,16]

The last evidence-based guidelines (S3, 2018) positioned PRP as having a level of evidence of 3 in both AGA and FPHL.^[17] The purported reason for the low evidence level is attributable to the heterogeneity in treatment cohorts, nonstandardized preparation methods, inadequate outcome variables, and qualitative studies exceeding quantitative data. However, a recent systematic review and meta-analysis has labeled PRP as a Level 1 (a) Evidence-Based Medicine, and further research would definitely focus on standardizing regenerative therapy.^[18]

Mechanism of action of PRP in AGA

PRP is a fraction of blood plasma that has concentration of platelets higher than the baseline.^[2] Unlike their previous understanding, platelets have no longer been associated with only hemostasis. They are now known to be a storehouse of GFs. These GFs are released on degranulation of the platelets. They affect the microenvironment of the tissue they are released in by causing cell proliferation, differentiation, migration, and angiogenesis.^[19] Some of the most significant GFs released by the platelets include platelet-derived growth factor (PDGF), vascular endothelial growth factor, fibroblast growth factor (FGF), epidermal growth factor (EGF), hepatocyte growth factor, insulin-like growth factors 1 and 2 (IGF 1 and 2), and matrix metalloproteinases 2 and 9.^[2]

The hair cycle is regulated by numerous GFs. The bulge area of the hair follicle is thought to contain hair follicular stem cells. A study by Akiyama *et al.*^[20] examined the localization of GF receptor on the bulge stem cells in the human fetus. They found intense labeling of EGF and transforming growth factor- α (TGF- α) receptors on all the bulge cells, suggesting their role in growth and differentiation. They also found a differential labeling pattern of PDGF receptors, which implied their role in the interaction between the bulge and associated tissue.

Another pathway that plays an essential role in human hair follicle growth is the WNT/ β -catenin pathway. This pathway primarily functions during the embryonic hair morphogenesis.^[21] However, studies have also shown activation of the WNT/ β -catenin pathway during adult hair growth, specifically during anagen activation.^[22] The activation of the WNT pathway by WNT ligands leads to the stabilization of β -catenin. β -Catenin translocates to the nucleus and activates the multiple target genes responsible for the pleomorphic functions of the WNT pathway such as cellular proliferation, their migration, and maturation.^[23] In their study, Myung *et al.*^[22] showed that activation of WNT pathway was essential for the conversion of telogen hair to anagen hair and the deletion of *Wntless* gene (a gene required for secretion of WNT ligands) led to the arrest of hair follicles in the telogen phase. This embryonic pathway

is also activated in another process of hair regeneration called adult wound-induced hair neogenesis.^[21] Ito *et al.*^[21] demonstrated that new hairs could be generated *de novo* after wound healing. This follicular neogenesis required an intact WNT/ β -catenin pathway and overexpression of WNT ligand increased the number of regenerated follicles.

The third pathway that has found relevance in the hair growth is the ERK/Akt pathway. The extracellular signal-regulated kinase (ERK) and the protein kinase B (Akt) signaling promotes cellular proliferation and prevention of apoptosis.^[24]

Li *et al.*^[25] investigated the effect of PRP on hair growth by applying PRP to cultured DP cells. They found that PRP increased the proliferation of DP cells along with an increase in β -catenin levels and FGF-7 levels. They also detected stimulation of ERK and Akt signaling. PRP has also found to stimulate hair growth by angiogenesis and neovascularization.^[24] The downregulation of glycogen synthase-3 in PRP-treated DP cells was consistent with the activation of the WNT pathway.^[26]

The hair follicle growth occurs in the harmony of the various pathways. FGF-7 acts by prolonging the anagen phase, ERK signaling causes cellular proliferation, Akt activation leads to Bcl-2 release, which is antiapoptotic, and β -catenin stimulates hair follicle development.^[27,28] The other GFs stimulate hair follicular growth and neovascularization.

The types of GFs present in PRP and their main functions have been detailed in Table 1.

Scope of recommendations

There is a lack of standardization of preparation of PRP in the medical literature. Current reporting of methodology of PRP preparation and the composition of the final PRP product is inconsistent and insufficient for comparison between studies.^[29] There is a need for consensus on the various facets of PRP preparation. These recommendations are intended for dermatologists who are involved in

Table 1: Growth factors present in platelets and their prominent functions

Growth Factor	Function(s)
PDGF ^[26]	Promotes neovascularization and hair follicular separation, induction, and control of anagen
TGF- β ^[27]	Hair cell proliferation and regeneration
VEGF ^[26]	Increases perifollicular vascularization during anagen phase
EGF ^[19]	Hair cell proliferation
HGF ^[26]	Angiogenesis
FGF ^[26]	Induces and prolongs anagen phase of hair follicle
IGF-1 ^[26]	Stimulated angiogenesis

PDGF=platelet-derived growth factor, TGF- β = transforming growth factor- β , VEGF=vascular endothelial growth factor, EGF=epidermal growth factor, HGF=hepatocyte growth factor, FGF=fibroblast growth factor, IGF-1=insulin-like growth factor 1

the management of AGA using PRP. The goal of these recommendations is to provide a framework to practitioners for implementing useful, evidence-based recommendations for the preparation of PRP and its use in AGA.

Methodology of preparation of recommendations

A comprehensive literature search was done in the English language on the preparation of PRP and its use in AGA across multiple databases (PubMed, Embase, Medline, Google Scholar, and Cochrane). The search keywords used, alone or in combination, were “PRP,” “Platelet Rich Plasma,” “Platelet Concentrate,” “Androgenetic alopecia,” “Male pattern baldness,” “Hair loss,” and “Pattern baldness.” The grade of evidence and strength of recommendation was evaluated on the GRADE (Grading of Recommendation, Assessment, Development and Evaluation) framework.^[30] The quality of evidence and the strength of recommendation are shown in Table 2.^[31]

A draft was prepared, which was then sent for review to the members of IADVL taskforce for PRP, appointed by the IADVL Academy of Dermatology. It was also sent to the IADVL Academy members for critical comments. Based on the inputs, the final consensus statement was prepared. A total of 30 articles (meta-analyses, prospective and retrospective studies, reviews, chapters in books, and case series) were critically evaluated, and the evidence thus gathered was used in the preparation of these recommendations.

Preparation of PRP with reference to AGA

The manual double-spin method is the preferred method of preparation of PRP for AGA (Level of evidence – High, Strength of recommendation – Strong)

PRP prepared for AGA must be tailored to the needs of the disease. PRP must be prepared using a method that can produce the required platelet concentration preferably more than 1 million platelets per microliter and be produced in 5 to 7 mL volume so that an adequate area of the scalp can be covered. The manual double-spin method is the preferred method of preparation of PRP as it allows variation in the

volume of blood drawn and the volume of PRP prepared. This process involves drawing blood in sterile disposable tubes previously containing an anticoagulant and then spinning them in the centrifuge at low RPM. After the initial centrifugation, the supernatant is then transferred to two new sterile tubes, which are then taken up for second centrifugation at a higher RPM. This spin sediments the platelets in the form of a pellet. The top two-third part of the plasma is discarded (platelet-poor plasma), and the platelet pellet is redissolved in the lower one-third volume of the plasma, as shown in Figure 1.^[4]

When using a commercial kit to prepare PRP for AGA, the choice of the kit depends on the platelet yield and the volume of PRP produced by the commercial device. The devices with higher platelet yield and the ones that produce at least 5 to 7 mL of PRP must be chosen. In the case of devices that produce a PRP with a lower yield, 1 to 2 mL of the platelet-poor plasma can be discarded, and the platelet pellet may be redissolved in a lower volume of plasma, increasing the concentration. In case the volume of PRP produced is low, multiple tubes can be used at the same time, and their output can be combined. Gkini *et al.*^[32] used two gel separation kits and combined the PRP from these two tubes after discarding the top 2 mL of platelet-poor plasma to get 6 mL of PRP with a higher

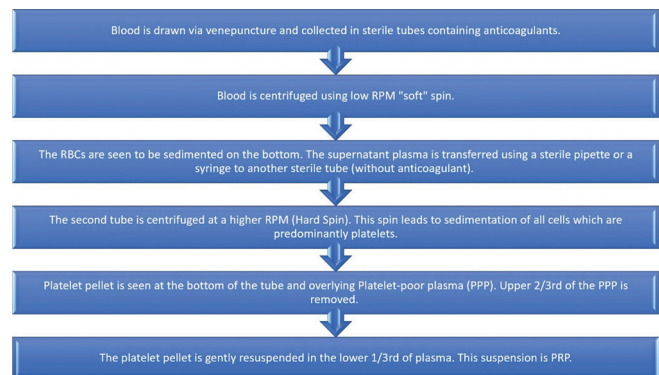


Figure 1: Step-by-step flow diagram of preparation of platelet-rich plasma using open double-spin method

Table 2: GRADE Framework

GRADE Framework	
A. Quality of evidence	
High quality	Well performed randomized control trials or clear evidence from multiple well-conducted observational studies showing very large effects
Moderate quality	Randomized control trials with essential limitations
Low quality	Observational studies or controlled trial with severe limitations
Very low quality	Nonsystematic observations, biologic reasoning, or observational studies with severe limitations
B. Strength of recommendation	
Strong	A strong recommendation was given when benefits distinctly outweighed the risks for nearly all patients. As practitioners, most patients must receive this course of action
Weak	A weak recommendation was given when risks and benefits were more closely balanced or were uncertain. As practitioners, patients must be explained about all the different options, and an option suitable for patients needs must be chosen

GRADE=Grading of Recommendation, Assessment, Development, and Evaluation

platelet amplification factor. This may lead the patient to incur additional costs.

The interval between sessions of PRP and the total number of sessions required for AGA

A minimum of three to five sessions of PRP are recommended for AGA with a gap of 1 month between two sessions (Level of evidence – High, Strength of recommendation – strong).

Various studies have performed PRP treatments at different intervals between sessions and a different number of sessions. Most of the studies that have shown positive responses for hair growth in PRP have done a minimum of three sessions.^[13,19,33] Two studies that have shown negative responses in PRP have performed either one or two sessions only.^[5] The optimum interval between two sessions is 1 month. The three high-quality RCTs have all given treatments at 1-month intervals and have shown positive results in hair growth.^[13,19,33] Few studies have done treatments at 2- to 3-week intervals; however, none of these studies were randomized.^[34,35,37,38] One study that performed weekly PRP sessions for six sessions had shown positive results only in two out of 10 cases.^[39] The ideal interval between two sessions must depend on the duration of GF release of PRP and speed of hair growth. Marx^[3] found that when platelets are externally activated, 95% of the GFs are released within 1 hour. However, when there is physiological activation of platelets, PRP continues to release GFs up to 10 days.^[40] The interval of either 2 weeks or 1 month may be chosen. However, because of the slow speed of hair growth (around 0.3 mm per day), it may be prudent to give monthly treatments.

Patient selection for PRP

Patients with Grade II to V Norwood Hamilton classification of AGA are the ideal subset for PRP (Level of evidence – High, Strength of recommendation – Strong).

Gentile *et al.*^[13] showed a positive response of PRP in male patients with pattern hair loss Stages II to IV. Similarly, Alves and Grimalt^[19] chose Stage II–V Hamilton Norwood and noted a positive response in hair growth and thickness. Betsi *et al.*^[41] observed more inadequate improvement in late stages of VI–VII Norwood Hamilton as compared with earlier stages and those who had onset of alopecia less than 2 years. Similar results were seen by Gkini *et al.*,^[32] who observed better results with Stages II–III cases. Sharma *et al.*,^[42] in their study, found 52% improvement in Norwood Hamilton Stages II to V, whereas only 38% improvement was seen in Norwood Hamilton Stages VI and VII. This difference was not statistically significant.

The volume and dose of PRP required

A total of 5 to 7 mL of PRP and 0.05 to 0.1 mL/cm² is the recommended dose of PRP for AGA (Quality of evidence – High, Strength of recommendation – Strong).

The majority of the randomized, controlled, blinded trials that have shown a positive effect of PRP in AGA have injected 0.05 to 0.1 mL of PRP per cm².^[13,19,33] Assuming the average area of the bald scalp to be 150 cm² [Figure 2], the volume of PRP required will be 7.5 mL (Volume of PRP injected per site × Area of scalp). A smaller volume may be required when the area of treatment is smaller. A volume of 5 to 7 mL is recommended. Distance between the injection sites has been uniformly used as 1 cm apart among all the studies.^[13,19,32,33,36]

Mode of injection

The recommended mode of injection of PRP in the scalp for AGA is with an insulin syringe or small-bore tuberculin syringes (Quality of evidence – High, Strength of recommendation – Strong).

The majority of the RCTs and various other studies have injected PRP on the scalp manually using syringes like insulin/tuberculin syringes.^[13,32,33] Gkini *et al.*^[32] have recommended the depth of injection as 1.5 to 2.5 mm. There is a controversy about the delivery of PRP with the help of microneedling. Dhurat *et al.*^[43] chose a 1 × 1 cm area of skin and performed a dermaroller treatment (1.5 mm). They rolled 20 times and then massaged the dye over the skin. They found that the maximum dye penetration was only 0.5 mm. Furthermore,

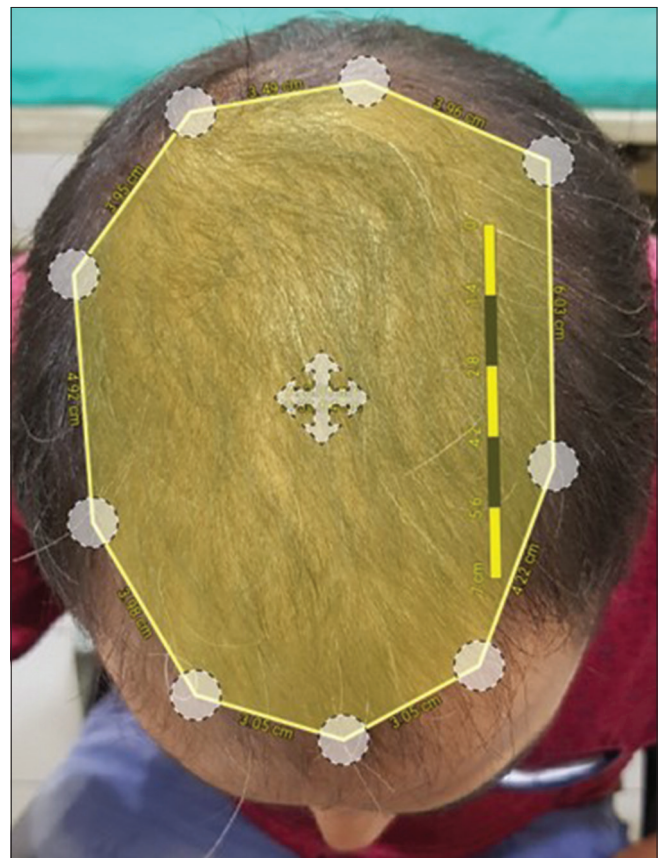


Figure 2: Calculation of area of scalp using open Image meter™ smartphone app. Average area comes out to be around 150 cm²

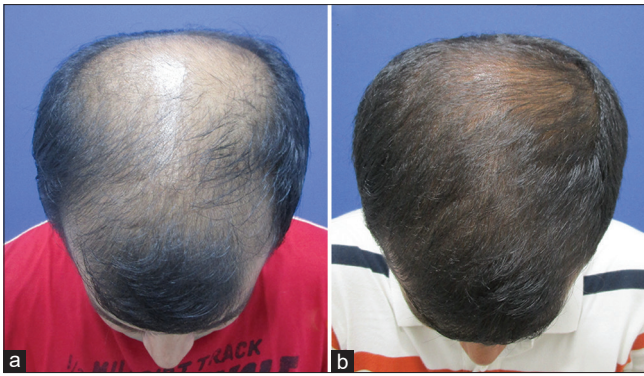


Figure 3: Photograph of vertex of a patient with androgenetic alopecia. (a) Before platelet-rich plasma (PRP) treatment. (b) After three sessions of PRP treatment

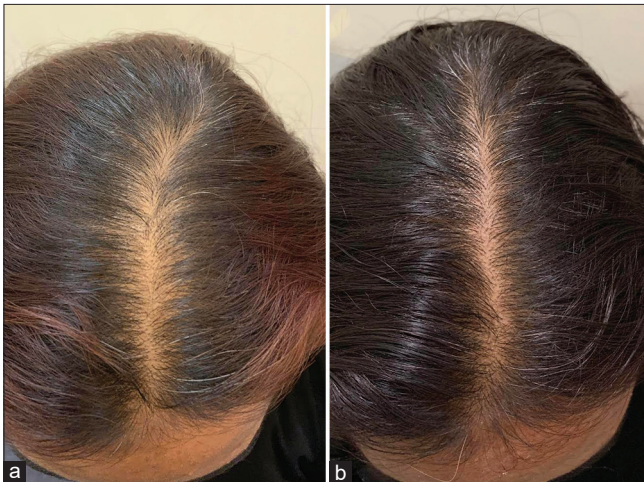

Figure 5: Before (a) and after (b) photos of a lady with female pattern hair loss treated with three sessions of platelet-rich plasma treatment

despite follicular dilatation by the roller, the dye could not pass below the level of the infundibulum. Sasaki^[44] have shown that the depth of the microneedle penetration is reliable and reproducible up to only 1 mm (mean depth of penetration was 0.92 mm for 1-mm microneedle and 1.1 mm for 2.5-mm microneedle). They showed that fluorescein-labeled platelets were able to penetrate deeper than the pigment dye particles (0.95 mm vs. 0.7 mm when using 1-mm microneedles). However, they were unable to produce deeper penetration even with longer needles reliably. Hence, it is not advisable to perform PRP treatment using microneedling as this process wastes a lot of PRP that is spread on the scalp and does not reliably deposit platelets below 1 mm depth. The targets of PDGFs are at the bulge level (approximately 2 mm deep) and at the hair root (approximately 4–5 mm deep). Hence, it is recommended to inject PRP with the help of insulin/tuberculin syringes where the depth can be easily controlled. When using an injection device such as Mesogun™, it is advisable to use point-by-point mode instead of nappage mode as this leads to wastage of precious PRP.

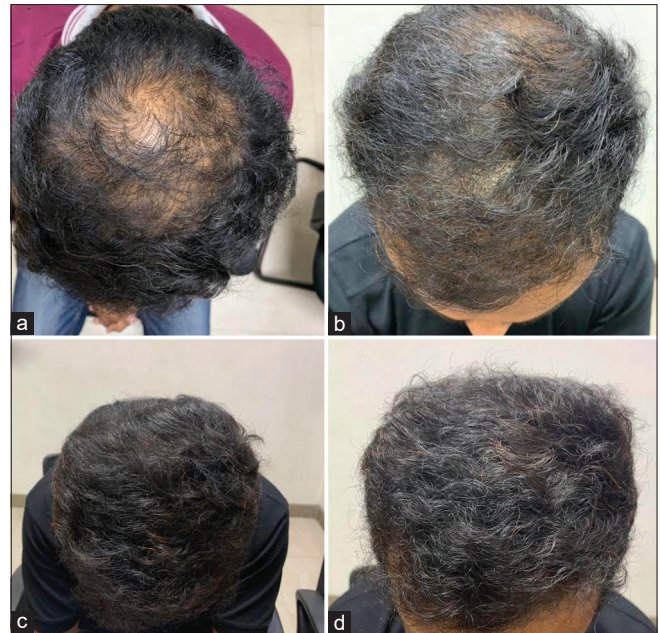

Figure 4: Serial photographs of a patient with androgenetic alopecia – Before (a, b) and after (c, d) six treatments of platelet-rich plasma treatment

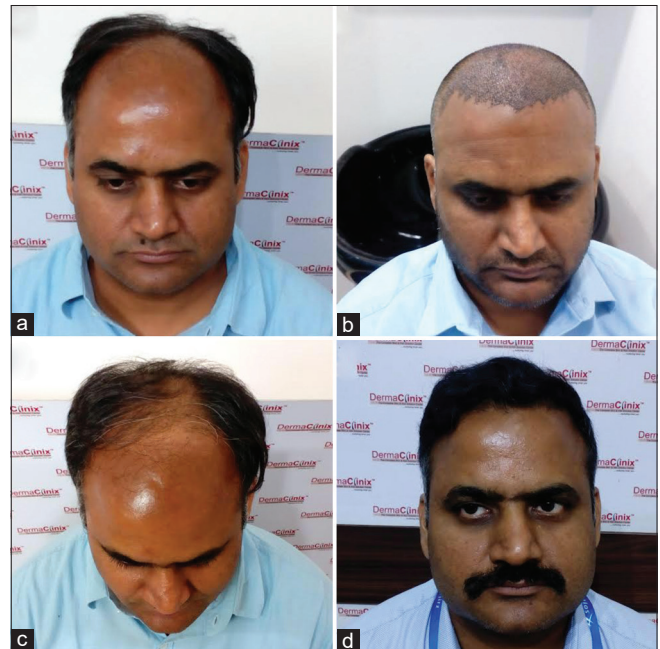

Figure 6: Photograph of a patient with androgenetic alopecia – before (a, b) and after (c, d) platelet-rich plasma and follicular unit extraction treatments

Need for platelet activation

Activation of PRP is not required when it is used for AGA (Quality of evidence – Medium, Strength of recommendation – Strong).

Platelet activation is not required when injecting in collagen-containing soft tissue such as the dermis.^[45] Gentile *et al.*^[13] compared the results of activated and nonactivated PRP and its use in AGA. They found a more significant

increase in hair count and hair density with nonactivated PRP than with activated PRP. The same PRP preparation device was used in both cases. This difference may be because of the slow activation of PRP by *in vivo* collagen Type I, leading to a prolonged release of GFs.^[46] Another reason may be that the endogenous activation of PRP may enable the production of thromboxane A2 (TXA2), which would activate additional platelets and amplify the platelet aggregation.^[13] When platelets are externally activated, 95% of the GFs are released within 1 hour.^[3] However, when there is physiological activation of platelets, PRP continues to release GFs up to 10 days.^[40]

Ideal platelet concentration in PRP for use in AGA

Around 1 to 1.5 million platelets/ μ L of platelets in PRP is the recommended platelet concentration in PRP for treatment of AGA (Quality of evidence – Low, Strength of recommendation – Strong).

Rughetti *et al.*^[47] found a proliferation of human-cultured umbilical vein endothelial cells that peaked at 1.5 million/ μ L platelet concentration. Xiao *et al.*^[26] studied the effect of PRP on cultured human hair DP cells and found 1.3 million/ μ L platelets in PRP to be the ideal concentration for DP cell proliferation. They observed that when PRP was added at 10% of the culture volume, the highest proliferation was seen. A study by Wang *et al.*^[48] confirmed this finding. This finding also hints toward the ideal volume of PRP to be injected, that is 0.1 mL per cubic centimeter of skin tissue (10% PRP). A higher concentration of platelets in PRP was found to be inhibitory in all the above studies. Gkini *et al.*^[32] in the study, showed a positive response to PRP in AGA. They had a mean platelet concentration of 1.1 million/ μ L platelets in their PRP. Serial photographs of male and female patients where PRP was used for AGA and FPHL, respectively, by the expert panel [Figures 3-5].

L-PRP versus P-PRP for AGA

L-PRP is recommended for use in AGA (Level of evidence – low, Strength of recommendation – weak).

The role of leukocytes in PRP, and their positive or negative effects in AGA, is currently under debate in the literature. Some authors who oppose the use of L-PRP and suggest that neutrophils release reactive oxygen species and other proinflammatory cytokines that may lead to inflammation and destruction of tissue.^[10,49] Other authors support the presence of leukocytes in PRP as they may provide protection from infection and increase GF release and contribute to angiogenesis and cell proliferation.^[10] Magalon *et al.*^[50] in their landmark study, proposed the DEPA (Dose of injected platelets, Efficiency of production, Purity of the PRP, Activation of the PRP) classification and classify the various commercial devices available based on their platelet purity and platelet yield. They found that none of the methods reached the A rank (highest rank) in all three categories. They found that methods that prepare high

platelet yields are not pure, and methods that prepare P-PRP have a low yield. The reason behind this may be because of a different population of platelets as described by Karpatkin and Charmatz^[51] This population of heavier platelets may get trapped in the upper RBC layer, and hence their retrieval may be difficult if purity is required. Miron *et al.*^[52] also showed in their study that the specific gravity of platelets ranges from 1,040 to 1,065 kg/m³, whereas the density of white blood cells ranges from 1,055 to 1,085 kg/m³. This overlap in specific gravity leads to the accumulation of many platelets in buffy coats. In an attempt to prepare P-PRP, we may be missing many platelets.

I-PRF in AGA

I-PRF or injectable PRF was described by Miron *et al.*,^[53] where they centrifuged blood without any anticoagulant and in special plastic tubes that slowed the clotting process of blood. Blood was spun at low speeds, 60G for 3 minutes. This led to a liquid PRF solution that takes around 15 to 20 minutes to clot. This liquid form of PRF has been shown to produce more cumulative GFs than PRP and releases them in a much more controlled way.^[54] This is extremely beneficial for diseases such as AGA, where hair growth is slow. However, the platelet concentration amplification is much lower than PRP (2.7-fold in I-PRF vs. 5- to 6-fold in PRP).^[55] Few case reports by Arora and Shukla^[55] and Shashank and Bhushan^[56] have shown a positive response in male patients with AGA. Schiavone *et al.*,^[57] in their controlled study have shown good response in patients of hair loss in both sexes and all ages. Further research is required in this field to establish the utility of I-PRF in hair loss and other dermatological conditions.

Combining PRP with monofilament polydioxanone (PDO) threads

Thread lifts are frequently employed in aesthetic dermatology to effect nonsurgical face and body lifting. Combining threads with PRP has found some utility in AGA.^[58] Threads and their sutures induce neocollagenesis via sustained foreign body reaction and also improve microcirculation. All these mechanisms are capable of causing hair growth. This embedment of threads acts as a natural bioscaffold for the autologous GFs in PRP, thereby acting as a sustained-release GF model.^[59] This can reduce the frequency of PRP administration to quarterly or 6 monthly, in lieu of monthly; not to mention the synergistic action of PRP and thread embedment. It is pertinent to note that 6-monthly repetitions might be needed for the combination to prove effective, which runs the risk of inducing fibrosis, which in turn might affect the future prospects of the patient for hair transplantation.

PRP in hair transplantation

PRP is gaining interest in the past decade due to its inherent potential to restore hair growth through the release of GFs and cytokines that act on the stem cells in the bulge

area stimulating development of new follicles, promoting neovascularization and wound healing.

PRP has been used in hair transplantation in the following ways:

1. Adding PRP to the storage solution
2. Bathing follicles in PRP before implantation
3. Injecting PRP immediately after surgery
4. Putting PRP in the donor area

Recent studies have suggested that statistically significant improvements in hair density and stimulation of hair growth occur when follicular units are pretreated with platelet plasma GFs before implantation.^[60]

PRP can be injected after making slits or at the end of surgery. In a single-blind, prospective, randomized study on 40 follicular unit extraction hair transplant subjects, PRP was injected intraoperatively immediately after creating slits over the recipient area in the PRP group and normal saline in the non-PRP group. In the PRP group, all subjects had >75% hair regrowth at 6 months, whereas in the non-PRP group, only four patients had >75% hair regrowth at 6 months. The number of patients having lengthier hairs was significantly more in the PRP group.^[61] Serial photographs of patients where a combination of PRP and FUE was used for AGA by the expert panel [Figure 6].

Comparison of PRP and other nonsurgical modalities

A recent meta-analysis compared different RCTs that used PRP for the treatment of AGA and compared the new hair growth as compared with baseline to be 33 hair/cm² (range of 21–111 hair/cm²).^[62] Another meta-analysis compared different FDA-approved modalities for the treatment of AGA.^[63] On comparison, the PRP produced more hair growth compared with 1 mg finasteride daily (18.37 hair/cm²), 5% minoxidil 1 mL twice a day (14.94 hair/cm²), low-level laser therapy (17.66 hair/cm²), and 2% minoxidil 1 mL twice a day (8.11 hair/cm²). Starace *et al.*^[64] showed new hair growth treated with PRP in women with FPHL that failed to respond to minoxidil. Furthermore, a combination of PRP with topical minoxidil yielded significantly superior results when compared with minoxidil monotherapy on clinotrichoscopic evaluation in a large study ($n = 100$) conducted by Ray and Sharma.^[65] Minimal adverse effects of PRP as compared with other modalities such as finasteride (loss of libido and erectile dysfunction) make it a reasonable treatment modality in hair loss.

Conclusion

To conclude, the way forward is to marginalize expectations and to not pressurize PRP for use as a stand-alone therapy. As AGA is a complicated disorder with complex etiopathogenetic mechanisms, a multipronged approach must be, and is, employed therapeutically, and PRP should feature in the cafeteria approach offered for the same. As

per Robert Miles's famous words, we have "miles to go before we sleep" and these literary miles would only be traversed when we continue to pool knowledge and publish good quality literature targeted specifically at standardizing preparation and producing a final product with properties that are reproducible and redundant.

Financial support and sponsorship

Nil.

Conflicts of interest

There are no conflicts of interest.

References

1. Agrawal AA. Evolution, current status and advances in application of platelet concentrate in periodontics and implantology. *World J Clin Cases* 2017;5:159-71.
2. Alves R, Grimalt R. A review of platelet-rich plasma: History, biology, mechanism of action, and classification. *Skin Appendage Disord* 2018;4:18-24.
3. Marx RE. Platelet-rich plasma (PRP): What is PRP and what is not PRP? *Implant Dent* 2001;10:225-8.
4. Dhurat R, Sukesh M. Principles and methods of preparation of platelet-rich plasma: A review and author's perspective. *J Cutan Aesthetic Surg* 2014;7:189-97.
5. Garg S, Manchanda S. Platelet-rich plasma-an "Elixir" for treatment of alopecia: Personal experience on 117 patients with review of literature. *Stem Cell Investig* 2017;4:64.
6. Elghblawi E. Platelet-rich plasma, the ultimate secret for youthful skin elixir and hair growth triggering. *J Cosmet Dermatol* 2018;17:423-30.
7. PRP News, Research and Information – Before Surgery. com PRP Regeneration Therapy Resources. Available from: <http://beforesurgery.com/news-specials>. [Last accessed on 2020 Nov 29].
8. Anitua E. Plasma rich in growth factors: Preliminary results of use in the preparation of future sites for implants. *Int J Oral Maxillofac Implants* 1999;14:529-35.
9. Sánchez M, Anitua E, Azofra J, Aguirre JJ, Andia I. Intra-articular injection of an autologous preparation rich in growth factors for the treatment of knee OA: A retrospective cohort study. *Clin Exp Rheumatol* 2008;26:910-3.
10. Dohan Ehrenfest DM, Rasmusson L, Albrektsson T. Classification of platelet concentrates: From pure platelet-rich plasma (P-PRP) to leucocyte- and platelet-rich fibrin (L-PRF). *Trends Biotechnol* 2009;27:158-67.
11. Giordano S, Romeo M, di Summa P, Salvati A, Lankinen P. A Meta-analysis On Evidence Of Platelet-rich Plasma for Androgenetic Alopecia. *Int J Trichology* 2018;10:1-10.
12. Dervishi G, Liu H, Peternel S, Labeit A, Peinemann F. Autologous platelet-rich plasma therapy for pattern hair loss: A systematic review. *J Cosmet Dermatol* 2020;19:827-35.
13. Gentile P, Garcovich S, Bielli A, Scioli MG, Orlandi A, Cervelli V. The effect of platelet-rich plasma in hair regrowth: A randomized placebo-controlled trial. *Stem Cells Transl Med* 2015;4:1317-23.
14. Qu Q, Shi P, Yi Y, Fan Z, Liu X, Zhu D, *et al.* Efficacy of platelet-rich plasma for treating androgenic alopecia of varying grades. *Clin Drug Investig* 2019;39:865-72.
15. Van Neste D. Viable terminal scalp hair follicles constitute a necessary and sufficient biological end-organ that conditions

- clinical efficacy of finasteride in males with male pattern hair loss without implying reversal of miniaturized follicles. *Skin Res Technol* 2019;25:701-11.
16. Shanshanwal SJ, Dhurat RS. Superiority of dutasteride over finasteride in hair regrowth and reversal of miniaturization in men with androgenetic alopecia: A randomized controlled open-label, evaluator-blinded study. *Indian J Dermatol Venereol Leprol* 2017;83:47.
 17. Kanti V, Messenger A, Dobos G, Reygagne P, Finner A, Blumeyer A, *et al.* Evidence-based (S3) guideline for the treatment of androgenetic alopecia in women and in men-short version. *J Eur Acad Dermatol Venereol J* 2018;32:11-22.
 18. Gentile P, Garcovich S. Systematic review of platelet-rich plasma use in androgenetic alopecia compared with minoxidil[®], Finasteride[®], and adult stem cell-based therapy. *Int J Mol Sci* 2020;21:2702.
 19. Alves R, Grimalt R. Randomized placebo-controlled, double-blind, half-head study to assess the efficacy of platelet-rich plasma on the treatment of androgenetic alopecia. *Dermatol Surg* 2016;42:491-7.
 20. Akiyama M, Smith LT, Holbrook KA. Growth factor and growth factor receptor localization in the hair follicle bulge and associated tissue in human fetus. *J Invest Dermatol* 1996;106:391-6.
 21. Ito M, Yang Z, Andl T, Cui C, Kim N, Millar SE, *et al.* Wnt-dependent de novo hair follicle regeneration in adult mouse skin after wounding. *Nature* 2007;447:316-20.
 22. Myung PS, Takeo M, Ito M, Atit RP. Epithelial Wnt ligand secretion is required for adult hair follicle growth and regeneration. *J Invest Dermatol* 2013;133:31-41.
 23. Van Amerongen R, Nusse R. Towards an integrated view of Wnt signaling in development. *Dev Camb Engl* 2009;136:3205-14.
 24. Gupta AK, Carviel J. A mechanistic model of platelet-rich plasma treatment for androgenetic alopecia. *Dermatol Surg* 2016;42:1335-9.
 25. Li ZJ, Choi H-I, Choi D-K, Sohn K-C, Im M, Seo Y-J, *et al.* Autologous platelet-rich plasma: A potential therapeutic tool for promoting hair growth. *Dermatol Surg* 2012;38:1040-6.
 26. Xiao S-E, Miao Y, Wang J, Jiang W, Fan Z-X, Liu X-M, *et al.* As a carrier-transporter for hair follicle reconstitution, platelet-rich plasma promotes proliferation and induction of mouse dermal papilla cells *Sci Rep* 2017;7:1125.
 27. Gentile P, Garcovich S. Advances in regenerative stem cell therapy in androgenic alopecia and hair loss: Wnt pathway, growth-factor, and mesenchymal stem cell signaling impact analysis on cell growth and hair follicle development. *Cells* 2019;8:466.
 28. Graziani F, Ivanovski S, Cei S, Ducci F, Tonetti M, Gabriele M. The *in vitro* effect of different PRP concentrations on osteoblasts and fibroblasts. *Clin Oral Implants Res* 2006;17:212-9.
 29. Kramer ME, Keane TC. Systematic review of platelet-rich plasma (PRP) preparation and composition for the treatment of androgenetic alopecia. *J Cosmet Dermatol* 2018;17:666-71.
 30. Atkins D, Best D, Briss PA, Eccles M, Falck-Ytter Y, Flottorp S, *et al.* Grading quality of evidence and strength of recommendations. *BMJ* 2004;328:1490.
 31. Guyatt GH, Oxman AD, Kunz R, Falck-Ytter Y, Vist GE, Liberati A, *et al.* Going from evidence to recommendations. *BMJ* 2008;336:1049-51.
 32. Gkini M-A, Kouskoukis A-E, Tripsianis G, Rigopoulos D, Kouskoukis K. Study of platelet-rich plasma injections in the treatment of androgenetic alopecia through an one-year period. *J Cutan Aesthetic Surg* 2014;7:213-9.
 33. Cervelli V, Garcovich S, Bielli A, Cervelli G, Curcio BC, Scioli MG, *et al.* The effect of autologous activated platelet rich plasma (AA-PRP) injection on pattern hair loss: Clinical and histomorphometric evaluation. *Bio Med Res Int* 2014;2014:760709.
 34. Mapar MA, Shahriari S, Haghighizadeh MH. Efficacy of platelet-rich plasma in the treatment of androgenetic (male-patterned) alopecia: A pilot randomized controlled trial. *J Cosmet Laser Ther* 2016;18:452-5.
 35. Puig CJ, Reese R, Peters M. Double-blind, placebo-controlled pilot study on the use of platelet-rich plasma in women with female androgenetic alopecia. *Dermatol Surg* 2016;42:1243-7.
 36. Singhal P, Agarwal S, Dhot PS, Sayal SK. Efficacy of platelet-rich plasma in treatment of androgenic alopecia. *Asian J Transfus Sci* 2015;9:159-62.
 37. Takikawa M, Nakamura S, Nakamura S, Ishirara M, Kishimoto S, Sasaki K, *et al.* Enhanced effect of platelet-rich plasma containing a new carrier on hair growth. *Dermatol Surg* 2011;37:1721-9.
 38. Gupta S, Revathi TN, Sacchidanand S, Nataraj HV. A study of the efficacy of platelet-rich plasma in the treatment of androgenetic alopecia in males. *Indian J Dermatol Venereol Leprol* 2017;83:412.
 39. Marwah M, Godse K, Patil S, Nadkarni N. Is there sufficient research data to use platelet-rich plasma in dermatology? *Int J Trichology* 2014;6:35-6.
 40. Kobayashi E, Flückiger L, Fujioka-Kobayashi M, Sawada K, Sculean A, Schaller B, *et al.* Comparative release of growth factors from PRP, PRF, and advanced-PRF. *Clin Oral Investig* 2016;20:2353-60.
 41. Betsi E-E, Germain E, Kalbermatten D, Tremp M, Emmenegger V. Platelet-rich plasma injection is effective and safe for the treatment of alopecia. *Eur J Plast Surg* 2013;36:407-12.
 42. Sharma VK, Bhari N, Patra S, Parihar AS. Platelet-rich plasma therapy for androgenetic alopecia. *Indian J Dermatol* 2019;64:417-9.
 43. Dhurat R, Sharma A, Goren A, Daruwalla S, Situm M, Kovacevic M. Mission impossible: Dermal delivery of growth factors via microneedling. *Dermatol Ther* 2019;32:e12897.
 44. Sasaki GH. Micro-needling depth penetration, presence of pigment particles, and fluorescein-stained platelets: Clinical usage for aesthetic concerns. *Aesthet Surg J* 2017;37:71-83.
 45. Marlovits S, Mousavi M, Gäbler C, Erdős J, Vécsei V. A new simplified technique for producing platelet-rich plasma: A short technical note. *Eur Spine J* 2004;13(Suppl 1):S102-6.
 46. Cavallo C, Roffi A, Grigolo B, Mariani E, Pratelli L, Merli G, *et al.* Platelet-rich plasma: The choice of activation method affects the release of bioactive molecules. *BioMed Res Int* 2016;2016:6591717.
 47. Rughetti A, Giusti I, D'Ascenzo S, Leocata P, Carta G, Pavan A, *et al.* Platelet gel-released supernatant modulates the angiogenic capability of human endothelial cells. *Blood Transfus* 2008;6:12-7.
 48. Wang Y, Tang L, Zhu F, Jia M. Platelet-rich plasma promotes cell viability of human hair dermal papilla cells (HHDPCs) *in vitro*. *Int J Clin Exp Pathol* 2017;10:11703-9.
 49. Zhou Y, Zhang J, Wu H, Hogan MV, Wang JH-C. The differential effects of leukocyte-containing and pure platelet-rich plasma (PRP) on tendon stem/progenitor cells-implications of PRP application for the clinical treatment of tendon injuries. *Stem Cell Res Ther* 2015;6:173.
 50. Magalon J, Chateau AL, Bertrand B, Louis ML, Silvestre A,

- Giraud L, *et al.* DEPA classification: A proposal for standardising PRP use and a retrospective application of available devices. *BMJ Open Sport Exerc Med* 2016;2:e000060.
51. Karpatkin S, Charnatz A. Heterogeneity of human platelets. *J Clin Invest* 1969;48:1073-82.
52. Miron RJ, Chai J, Zhang P, Li Y, Wang Y, Mourão CF de AB, *et al.* A novel method for harvesting concentrated platelet-rich fibrin (C-PRF) with a 10-fold increase in platelet and leukocyte yields. *Clin Oral Investig* 2020;24:2819-28.
53. Miron RJ, Bishara M, Choukroun J. Basics of platelet-rich fibrin therapy. *Dent Today* 2017;36:74-6.
54. Miron RJ, Fujioka-Kobayashi M, Hernandez M, Kandalam U, Zhang Y, Ghanaati S, *et al.* Injectable platelet rich fibrin (i-PRF): Opportunities in regenerative dentistry? *Clin Oral Investig* 2017;21:2619-27.
55. Arora R, Shukla S. Injectable-platelet-rich fibrin-smart blood with stem cells for the treatment of alopecia: A report of three patients. *Int J Trichology* 2019;11:128-31.
56. Shashank B, Bhushan M. Injectable Platelet-Rich Fibrin (PRF): The newest biomaterial and its use in various dermatological conditions in our practice: A case series. *J Cosmet Dermatol* 2021;20:1421-6.
57. Schiavone G, Paradisi A, Ricci F, Abeni D. Injectable Platelet-, Leukocyte-, and Fibrin-Rich Plasma (iL-PRF) in the management of androgenetic alopecia. *Dermatol Surg* 2018;44:1183-90.
58. Khattab FM, Bessar H. Accelerated hair growth by combining thread monofilament and minoxidil in female androgenetic alopecia. *J Cosmet Dermatol* 2020;19:1738-44.
59. Bharti J, Sonthalia S, Patil P, Dhurat R. Scalp threading with polydioxanone monofilament threads: A novel, effective and safe modality for hair restoration. *J Eur Acad Dermatol Venereol* 2017;31:e492-3.
60. Abdelkader R, Abdalbary S, Naguib I, Makarem K. Effect of platelet rich plasma versus saline solution as a preservation solution for hair transplantation. *Plast Reconstr Surg Glob Open* 2020;8:e2875.
61. Garg S. Outcome of intra-operative injected platelet-rich plasma therapy during follicular unit extraction hair transplant: A prospective randomised study in forty patients. *J Cutan Aesthetic Surg* 2016;9:157-64.
62. Evans AG, Mwangi JM, Pope RW, Ivanic MG, Botros MA, Glassman GE *et al.* Platelet-rich plasma as a therapy for androgenic alopecia: A systematic review and meta-analysis. *J Dermatolog Treat* 2020;26:1-14.
63. Adil A, Godwin M. The effectiveness of treatments for androgenetic alopecia: A systematic review and meta-analysis. *J Am Acad Dermatol* 2017;77:136-41.e5.
64. Starace M, Alessandrini A, D'Acunto C, Melandri D, Bruni F, Patrizi A, *et al.* Platelet-rich plasma on female androgenetic alopecia: Tested on 10 patients. *J Cosmet Dermatol* 2019;18:59-64.
65. Ray R, Sharma A. Comparison of 5% minoxidil lotion monotherapy versus its combination with autologous platelet rich plasma in androgenetic alopecia in hundred males. *Med J Armed Forces Ind* 2021;77:355-62.